

---

# Stem Cell Therapy for Cerebral Palsy – A Novel Option

---

Alok Sharma, Hemangi Sane,  
Nandini Gokulchandran, Prerna Badhe,  
Pooja Kulkarni and Amruta Paranjape

Additional information is available at the end of the chapter

<http://dx.doi.org/10.5772/57152>

---

## 1. Introduction

Discovery of stem cells by James Till and Ernest McCulloch in 1961, stands as one of the most remarkable medical-research achievements of the 20th century. This discovery provided a foundation for further breakthroughs in the field of stem cells. Sir Martin J. Evans along with Mario R. Capecchi, and Oliver Smithies were jointly awarded a Nobel Prize in 2007 for their contribution in introducing specific gene modifications in mice by the use of embryonic stem cells. Later in 2012, John B. Gurdon and Shinya Yamanaka were also jointly awarded a Nobel Prize for discovering that mature cells can be reprogrammed to become pluripotent cells. [1]

Ramon y Cajal in 1926 stated “Once the development was ended, the founts of growth and regeneration of the axons and dendrites dried up irrevocably. In the adult centers, the nerve paths are something fixed, ended, and immutable. Everything may die, nothing may be regenerated. It is for the science of the future to change, if possible, this harsh decree.” [2]. It was a long-standing belief that cells of the central nervous system once damaged cannot be regenerated. The medical science of stem cells has finally made restoration of CNS possible which has changed the old concept of medicine. Not too long ago, this therapy was hamstrung by various controversies, ethical and moral issues. But, tremendous progress of research in this field has finally led to its translation from laboratory to innovative cellular therapies.

A variety of cells including embryonic stem cells, adult stem cells, umbilical cord blood cells and induced pluripotent stem cells have been explored as a therapeutic alternative for treating a broad spectrum of neurologic disorders including stroke, Alzheimer’s, Parkinson’s, spinal cord injury, cerebral palsy etc. amongst others. It is essential to select suitable cells depending on the nature and status of neurological dysfunctions to achieve optimal therapeutic efficacy. Along with the selection of cells, the route of administration also plays an important role to

maximize the clinical therapeutic effect of the cell therapy. Numerous preclinical studies have been carried out to study the safety of intrathecal, intravenous and direct cerebral implantation. A plethora of published literature is also available to provide evidence of stem cells initiating functional restoration of CNS. The postulated mechanisms of action involved are neuromodulation, neuroprotection, axon sprouting, neural circuit reconstruction, neurogenesis, neuroregeneration, neurorepair, and neuroreplacement.

In view of the fact that stem cell therapy has a promising therapeutic potential in the treatment of neurological disorders, it is important for all the professionals in the medical field to understand the concepts of this upcoming therapeutic strategy.

In this chapter, we have focused on stem cell therapy for Cerebral Palsy (CP) which is a heterogeneous group of neurological disorders mainly observed in infants. It results due to a static brain lesion at the time of pregnancy or early life. The survival of CP children has increased due to advanced modern medicine which has led to their growing population. CP involves impairment of movement, muscle function, and cognitive functioning and the effects range from mild to severe. [3] Chronic motor disability along with intellectual disability, epilepsy, behavioral disorders, and sensory and perceptual disturbances are few of the complications seen in these patients. No biological intervention has been effective for CP and the standard approach is limited to supportive management strategies which do not address the core issue of neural tissue damage. Currently, stem cell based strategies have garnered attention due to their ability of neuroregeneration and neuroprotection in CP.

We have discussed the clinical aspects of stem cell therapy in cerebral palsy supported by various human case studies and clinical trials. We have also enumerated our experience and results wherein our subjects were administered autologous bone marrow mononuclear cells. In our study it was found to be safe, feasible and efficacious and may be used as a combinatorial strategy with the currently available standard treatments.

Here, we try to summarize the current vast knowledge available for stem cell therapy in cerebral palsy.

## 2. Stem cells

Stem cells are defined as “cells that have the ability to renew them continuously and possess pluripotent or multipotent ability to differentiate into many cell types.” [4] These cells exhibit a unique property of “plasticity” where in cells isolated from one tissue convert to cells of different tissues by crossing lineage barriers and adopting the expression profile and phenotype of cells that are unique to other tissues. [5]

Stem cells are categorized based on their potential to differentiate into other types of cells.

1. Totipotent cells: These cells have the ability to differentiate into all possible cell types of the human body including extra embryonic and placental cells.

2. Pluripotent cells: These cells have ability to differentiate into any of the three germ layers viz. endoderm, mesoderm and ectoderm.
3. Multipotent cells: These cells have the ability to differentiate into specialized cells.
4. Oligopotent cells: These cells have the ability to differentiate into a few cell types.
5. Unipotent cells: These cells have the ability to produce cells only of their own type, but are capable of self-renewal to be classified as a stem cell.

### 2.1. Types of stem cells

Stem cells are broadly classified based on their source, as follows:

- i. **Embryonic stem cells (ESCs):** These cells are pluripotent cells derived from a 4-7 day old blastocyst stage embryo. The cells are harvested from the inner cell mass (ICM) of the blastocyst. *In vitro*, they can be indefinitely maintained and expanded as pure populations of undifferentiated cells. [6] In spite of their great potency in tissue repair, these cells have triggered various ethical and moral issues due to the destruction of human embryos involved. [7] They also have tumorigenic side effects as ESCs and tumor cells share cellular and molecular phenotypes such as rapid proliferation rate, lack of contact inhibition, a susceptibility to genomic instability, high activity of telomerase, high expression of oncogenes and epigenetic status amongst others. They form teratomas which have the potential to degenerate into malignant teratocarcinomas [8] The likelihood of development of tumors in children cannot be overlooked as they have many years of life ahead of them for the tumor formation to occur.
- ii. **Fetal Stem Cells:** These cells are isolated either from the aborted fetus or from the extra embryonic structures of the fetal origin such as the amniotic fluid and placenta. Fetal blood is a rich source of haemopoietic stem cells (HSC). Non-haemopoietic mesenchymal stem cells (MSC) are also found in the first trimester fetal blood. [9] These cells have better homing capacity, greater multipotentiality and differentiation potential and lower immunogenicity as compared to the allogeneic adult stem cells. [10] Although these cells have a greater therapeutic potential they may also be associated with infections. These cells are prone to KS-associated herpes virus (KSHV) infections. [11] As the safety is not yet substantiated, fetal cells are not often used for transplantation. Use of fetal cells is ethically controversial as it is associated with abortion. Research on fetal cells is permitted only after the decision of abortion is made.
- iii. **Umbilical cord:** Umbilical cord contains a heterogeneous mixture of stem/progenitor cells at different lineage commitment stages. Cells are isolated either from the cord blood or the Wharton jelly. They consist of embryonic stem cell-like and other pluripotential stem cells, which can give rise to hematopoietic, epithelial, endothelial, and neural tissues. [12] Various banks have evolved to collect and preserve the umbilical cord blood. But the utility of these centers is still questionable. The protocols and guidelines for collection and retrieval of cells are still being standardized. Other

disadvantages of use of UCBCs are limited by the fact that minimum necessary dosage of cells for cell engraftment is  $1 \times 10^7$  cells per kilogram which includes the total nucleated cell fraction along with stem cells. Thus, the available dose of autologous cells obtained at birth may be insufficient for transplantation at an older age of the child [13].

Amount of stem cells found in the cord blood is 10% less than that obtained from the bone marrow. [14] There are some reports of associated Herpes virus and JC virus infection by allogeneic UCBCs transplantation [15,16]

- iv. **Induced pluripotent stem cells (iPSC):** To circumvent the ethical issues involved in the use of embryonic stem cells, pluripotent cells were generated directly from the patients' own cells. Induced pluripotent stem cells are non-pluripotent adult cells (somatic cells) which have been genetically reprogrammed to form pluripotent cells. The iPSC technology develops patient-specific cell therapy protocols. The availability of iPSCs is particularly advantageous for research involving neurological diseases, since it is difficult to obtain diseased tissue sample for study from living patients. [17]
- v. **Adult stem cells:** These cells are multipotent stem cells, isolated from adult tissues (i.e. after birth). They include hematopoietic stem cells, bone marrow derived stem cells, adipose tissue-derived stem cells, neural stem cells amongst others [18] Adult stem cells are found in almost all the tissues of the body and help to maintain and repair organs and tissues throughout a person's life. These cells are majorly found in the bone marrow, brain, skeletal muscle, liver, pancreas, fat, skin and skeletal muscle. The different types of adult stem cells include multipotent adult progenitor cells, oligodendrocyte progenitor cells neural stem cells, glial progenitor.

## 2.2. Major sources of adult stem cells

- i. **Bone marrow:** Anterior or posterior superior iliac crest is the preferred site for the bone marrow aspiration. If bone marrow cannot be obtained from the iliac crest due to positioning difficulties or obesity, sternum may be used in adults. However, aspiration from sternum poses a great risk of complication. [19]

Bone marrow is a proficient source of autologous cells with distinct regenerative properties, which can be quickly harvested and are thus applicable for both chronic and acute diseases. Cells isolated from the bone marrow not only differentiate into blood cells but also into neural tissues. [20] The mononuclear cell fraction derived from the bone marrow is a heterogeneous population containing differentially matured B-cells, T-cells and monocytes, as well as rare progenitor cells such as hematopoietic stem cells (HSC), mesenchymal stromal cells (MSC), endothelial progenitor cells (EPC) and very small embryonic-like cells (VSEL). The hematopoietic stem cells (HSCs) are the blood cells which give rise to the myeloid and lymphoid lineages. HSCs also have a potential to transdifferentiate into various nonhematopoietic cell lineages especially neural lineage. [21] [Figure1] Bone marrow mesenchymal stem cells (BMMSCs) give rise to mesodermal lineage cells such as osteoblasts, chondrocytes, adipocytes, and muscle cells along with neuroectodermal cells. [22] BMMSCs express a unique surface

molecule profile, including expression of CD13, CD29, CD44, CD49e, CD73, CD90, CD105, CD146, CD166, CD271, STRO-1, Octamer-4 (Oct4), and stage-specific embryonic antigen-4 (SSEA4). It is generally believed that BMMSCs are negative for hematopoietic cell markers such as CD14, CD34, c-kit, SCA1. [23]

It has been observed that use of cell mixture is more efficacious than individual sub fractionated cells of the bone marrow. They promote angiogenesis, mediate vascular repair, and express several cytoprotective growth factors and cytokines. These cells are also safe and due to its easy availability they are most preferred for cellular therapy. These cells are used for the treatment of various neurological disorders such as cerebral palsy, stroke, Parkinson's, Spinal cord injury, etc. along with diabetes, orthopedic conditions, cancers and wound healing. [24,25]

In brain injury, stem cells induce neuroprotection and neural repair by inflammatory suppression, causing tissue reconstruction of completely or partially damaged cells and prevent cell death. [26] On administration, these cells migrate to the injured tissue and initiate host repair and recovery through direct and indirect cell-cell signaling. [27] The safety of use of bone marrow derived cells has been well established as they have an autologous origin and do not result in tumor formation.

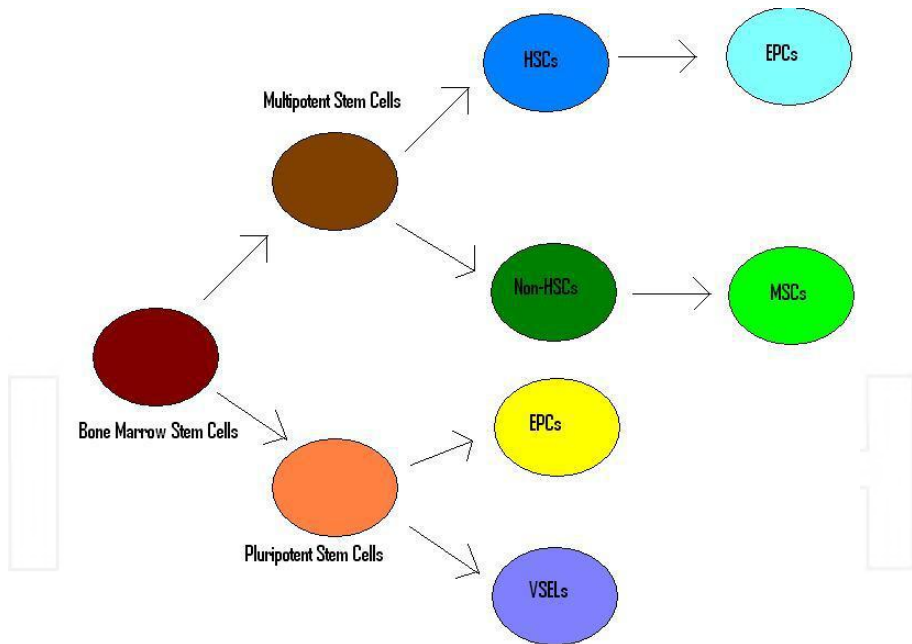


Figure 1. Bone marrow stem cells

- ii. **Adipose tissue:** Adipose tissue derived stem cells (ASCs) are multipotent cells, found abundantly in fat tissue. They can differentiate into several lineages, including

adipose cells, chondrocytes, osteoblasts, neuronal cells, endothelial cells, and cardiomyocytes. These cells are obtained either through liposuction or lipectomy. Mesenchymal stem cells make up the majority of the adipose derived stem cells. [28] Due to their plasticity, they are a preferred alternative to the BMSCs. [29] One of the major disadvantages of adipose derived stem cell is the isolating procedure. Therefore, a professional technician is required for cell isolation. In experimental cerebral palsy models, infusion of adipose derived stem cells has shown to improve physical activities and cognitive deficits. They have the ability to replace damaged oligodendrocytes and neurons without forming glial scars.[30]

- iii. **Dental pulp:** A population of stem cells has been isolated from the human dental pulp known as dental pulp stem cells (DPSCs). They have an ability to regenerate a dentin-pulp-like tissue. [31] DPSCs are a heterogeneous population of cells as they are composed of both mesenchymal and ectodermic cells. These cells are readily obtained from routine dental procedures such as removal of impacted third molars, deciduous teeth and have been shown to possess properties similar to neural stem cells and mesenchymal stem cells. [32] Under appropriate conditions, these cells also undergo neuronal differentiation. [33] One of the disadvantages of DPSCs is that it takes longer to culture mesenchymal stem cells from teeth active tissue. Also, it is difficult to harvest a large quantity of stem cells from teeth.
- iv. **Menstrual Blood stem cells:** Recently, stem cells have been identified from the endometrial tissue. The endometrial lining of the uterus has tremendous capacity of regeneration. The menstrual blood consists of a heterogeneous population of cells. However, isolation of these cells is a very invasive procedure. [34] Their potential in CP is not studied.
- v. **Peripheral blood stem cells:** Peripheral blood consists of circulating stem cells capable of restoring hematopoiesis. Hematopoietic stem cells obtained from PB by leukapheresis have been used for transplantation as an alternative to bone marrow-derived stem cells (BM-stem cells). The haemopoietic “potential” of PBSCs is equivalent to that of BM- stem cells [35] Their use in CP is not well established.

### 2.3. Various routes of administration of stem cells for cerebral palsy

The appropriate route of cell administration is essential prerequisite for the success of cellular therapy. For the treatment of cerebral palsy, cells are injected via various routes such as intrathecal, intravenous and intracerebral.

- i. **Intrathecal administration:** Intrathecal administration of cells involves delivery of cells via lumbar puncture. It is a minimally invasive procedure as compared to other routes of administration. This mode of injection allows efficient delivery of cells and the possibility of migration of cells to the tissues other than the damaged ones is avoided. [36]

This procedure needs to be done under aseptic condition to avoid any sort of infections. In case of cerebral palsy, it is considered to be the safe, feasible and efficacious route of admin-

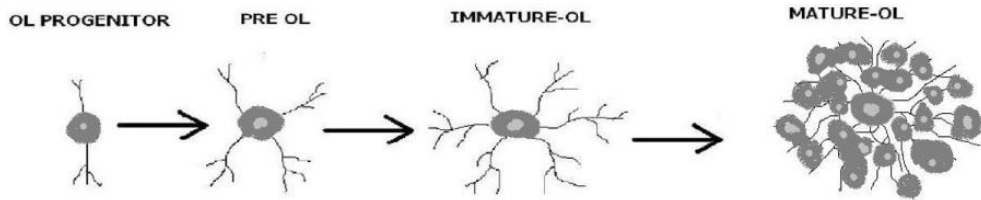
istration. In cerebral palsy, studies have shown that this route of administration results in positive functional outcomes. [37]

- ii. **Intravenous administration:** Intravenous system of delivery of cells has been widely used in cellular therapy due to its broad bio distribution and easy access. It is one of the most minimally invasive and safe modes of administration. Studies have shown that on administering cells intravenously, few cells reach the damaged site while a majority of cells get trapped in the lungs. Pulmonary passage could be one of the major hindrances for intravenous administration of stem cells. Hence, for effective result of intravenous stem cell transplantation, it is necessary to increase the number of cells injected. [38]
- iii. **Intracerebral administration:** In cerebral palsy, intracerebral transplantation of stem cells is carried out by injecting cells in the subventricular zone. This leads to migration of cells to the areas of ischemia but the outcome is not as remarkable as compared to the other minimally invasive procedures. Additionally, in CP the injury of the brain is diffused and a local injection could be focused on a particular area which might not be as effective. Intracerebral injection also increases the risk of bleeding and neural tissue injury. [39] Since, it is yet to establish cellular therapy as a cure, an invasive transplantation is not recommended due to the risks involved. Hence, a safer route of administration should be used.

#### 2.4. Mechanism of action of stem cells in cerebral palsy

To understand the mechanism of action of stem cells in the treatment of cerebral palsy, it is important to understand the empirical neuropathophysiology. In spite of the vast and varied etiology; underlying cellular mechanisms, that cause the morbidity or mortality associated with cerebral palsy, are tissue damage caused by hypoxia and ischemia. The clinical manifestations of this cellular damage, depends on a range of factors including the time of insult, the severity of insult and cause of the insult. Brain tissue is heterogeneous and responds differently to hypoxia and ischemia. Therefore, a certain type of brain tissue is implicated to cause cerebral palsy. Recent preclinical, immunohistochemical and imaging evidence suggests periventricular white matter injury (PWMI), particularly damage to oligodendrocytes (OLs) as a primary cause of cerebral palsy [40,41,42]. PWMI is a spectrum ranging from cystic focal necrotic lesions, periventricular leucomalacia (PVL) to specific cortical scarring in the deep regions of sulci, Ulegyria to diffuse myelination disturbances. Oligodendrocyte progenitors are abundantly present in the subventricular and periventricular zones, therefore damage to these cells is seen as PVL in neuroimaging investigations. The extent of the damage to the white matter and its consequences are dependent on the developmental stage at which the damage occurred, brain vascularization and the type of tissue[43].

Vascularization of the brain begins as early as 28<sup>th</sup> day of gestation with the formation of carotid arteries, followed by the large arteries, their branches, communicating arteries, long penetrating arteries and ends with the formation of short penetrating arteries in the post term period. Damage at pre term leads to focal cystic necrosis in the vascular end zones of the long



**Figure 2.** Phases of Oligodendrocyte development

penetrating arteries causing PVL, damage at term leads to tissue injury at the border zones of the long and short penetrating arteries giving rise to Ulegyria and damage at post term leads to diffuse myelination disturbances caused at the vascular end zones of short penetrating arteries [44]. Subsequently most vulnerable cells, precursors of Oligodendrocytes (OLs), undergo necrosis through apoptosis. This leads to myelination disturbances. Oligodendrocytes evolve through an established lineage of OL progenitors to pre OLs to immature OLs to mature OLs. [Figure 2] Hypoxic ischemia as observed in cerebral palsy leads to death of pre OLs and subsequent deficiency of mature OLs and myelination. Other cell types and mechanisms that contribute to pathophysiology of CP are axonal damage and microglial activation [45]. Following this primary insult to the nervous tissue, activation of glial cells leads to secretion of various chemical mediators of tissue necrosis in the neural microenvironment, leading to secondary white matter injury. These mediators are Reactive oxygen and nitrogen species, glutamates, adenosine and inflammatory cytokines like Tumor necrosis factor alpha ( $\text{TNF-}\alpha$ ), interferon gamma ( $\text{INF-}\gamma$ ), Interleukin -1 beta ( $\text{IL-1}\beta$ ) and superoxide radicals [46].

Cellular therapy regulates all of the above cellular mechanisms. Neuroplasticity of the brain is maximal during childhood. Hence, stem cell intervention is more successful in these children as the integration of new cells in the brain to carry out the repair process is more effective [47]. Stem cells possess the capacity to home onto the injured sites of brain, as guided by chemo attractant pathway [48]. The effects of cellular therapy are twofold, enhancing the brain tissue repair caused by various paracrine mechanisms and regeneration of neural tissue. Stem cells help in modifying the microglial response by exhibiting immunomodulatory, neurotrophic properties and enhance axonal sprouting. Various neurotrophic factors secreted by the stem cells are connective tissue growth factor, fibroblast growth factor 2 and 7 that are responsible for cell proliferation, interleukins responsible for cytoprotection [49,50,51]. Stem cell therapy restores lost myelin by replacing dead cells with new oligodendrocytes and their progenitors. Indirectly, it may also support their survival by introducing other cell types able to restore missing enzymes to an otherwise deficient environment [47]. Stem cell therapy also has an anti-inflammatory effect on the neural microenvironment as they reduce the levels of  $\text{TNF-}\alpha$ ,  $\text{IL-1}\beta$ ,  $\text{IL-1}\alpha$ ,  $\text{IL-6}$  and increased levels of  $\text{IL-10}$  [52]; therefore, enhancing the endogenous brain repair. Stem cells also secrete various growth factors like vascular endothelial growth factor (VEGF), fibroblast growth factor (FGF), brain fibroblast growth factor (bFGF). These growth factors initiate neoangiogenesis and induce secretion of hormones like erythropoietin. The cascade



events triggered due to these lead to formation of new vessels as well increased bold flow. Improved blood circulation of the brain thus helps retrieving the lost tissue functions [50].

### 3. Published literature

Several preclinical experiments on animal models of cerebral palsy have been carried out to demonstrate the potential of cell transplantation to minimize damage and promote recovery. However, limited clinical trials have been initiated to study the effect cell therapy in humans.

Human umbilical cord blood cells (hUCBCs) have been explored to a great extent in cerebral palsy. hUCBCs have been administered in rat models of neonatal hypoxia/ ischemia. They protect the mature neurons in the neocortex from injury, bring about near-normalization of brain damage in the subventricular zone (SVZ) leading to significant improvement in behavioral functions. The long lasting effect of these cells is due to the paracrine effects of hUCBCs which stimulate recovery in the injured brain and protect against further brain damage. [53] On transplantation, hUCBCs have shown to ameliorate neurological and motor deficits in CP model by reducing the levels of pro-inflammatory cytokines (Interleukin-1 $\alpha$  (IL-1 $\alpha$ ), Interleukin-1 $\beta$  (IL-1 $\beta$ ), and Tumor necrosis factor  $\alpha$  (TNF $\alpha$ )) [54,55]

They also alleviate spastic paresis in neonatal rat models resulting in normal walking [56] Studies have also shown that these cells promote neural stem cell proliferation via Sonic hedgehog (Shh) signaling pathway improving the brain damage. [57] Human umbilical cord blood (hUCB) cells have also shown to reduce sensorimotor deficits after hypoxic ischemic brain injury in neonatal rats. The dimensions of cortical maps and receptive fields, which are significantly altered after injury, are largely restored. Additionally, the lesion induced hyperexcitability is no longer observed in treated animals compared to control animals. The results demonstrate that hUCB cells reinstall the way central neurons process information by normalizing inhibitory and excitatory processes. [58] it is also observed that these cells exhibit a neuroprotective effect in the striatum, and decrease the number of activated microglial cells in the cerebral cortex of treated animals, further resulting in better functional recovery. [59] Tanaka et al, observed that CD133+ cells derived from hUCBCs reduce the cortical damage and also promote axonal growth in neonatal rat organ co-cultures exposed to hypoxia. [60]

Various preclinical studies have shown that transplantation of stem cells in the CP models lead to survival, homing and differentiation of these cells into neurons, oligodendrocytes, astrocytes etc.

Park et al reported clonal neural stem cells (NSCs) when transplanted into brains of postnatal hypoxic-ischemic (HI) injury mice, home preferentially to and integrate extensively within the ischemic areas. They differentiate into neurons and oligodendrocytes, the cell types damaged due to HI. [61] A chinese study, wherein neural stem cells derived from human fetal brain (hNSCs) were transplanted into cerebral ventricle of HI injury neonatal rat, too demonstrated the survival, migration and differentiation capacity of these cells in rat brain. [62] Similarly, Zheng et al showed that Multipotent astrocytic stem cells (MASCs) from mice transplanted

into a rat model of hypoxia-ischemia (HI) survive, migrate and differentiate into neurons and astrocytes. [63] In their study, Titomanlio et al implanted neurosphere-derived precursors in neonatal mouse model of cerebral palsy induced by excitotoxicity. They observed that cells migrated to the lesion site, remained undifferentiated at day 10, and differentiated into oligodendrocyte and neurons at day 42. Although grafted cells finally die there few weeks later, this procedure triggered a reduction in lesion size and an improvement in memory performance compared with untreated animals. [64] Chen et al, transplanted magnetically labeled mesenchymal stem cells in a model of perinatal brain injury. They found that these cells migrate to lesion sites and proliferate. They are neuroprotective and indirectly contribute to brain repair. [65]

Yasuhara et al, investigated the efficacy of intrahippocampal transplantation of bone marrow derived multipotent progenitor cells (MPCs) in HI injury. They found that transplanted MPCs ameliorated motor deficits associated with HI injury. [66] Webber et al in their study highlighted the protective effects of oligodendrocyte precursor cell transplantation in neonatal inflammation-induced rat model of periventricular leukomalacia. [67]

All the above preclinical studies have been carried out in animal models of acute hypoxic injury, hence showing significant results. But, similar results are difficult to replicate in human cases since the intervention always, cannot be carried out immediately post injury. Thus, more studies should be carried out in chronic injury models. Based on this observation, it can also be concluded that earlier the intervention, better is the outcome.

Below are few of the published studies carried out in human cases of cerebral palsy.

Luan et al carried out a study on 45 patients diagnosed with severe CP. They underwent transplantation of neural progenitor cell (NPC) derived from aborted fetal tissue. After 1 year, the developmental level in gross motor, fine motor, and cognition of the treatment group was significantly higher compared to the control group. These results suggested that NPC transplantation is a safe and effective therapeutic method for treating children with severe CP. [68]

Chen et al, injected neural stem cell-like (NSC-like) cells derived from autologous marrow mesenchymal stem cells in 30 cases of cerebral palsy. On follow up, they observed an increase in the GMFM scores and language quotients compared to the control group. No adverse events were recorded indicating that NSC-like cells are safe and effective for the treatment of motor deficits related to cerebral palsy. [69] Mink et al carried out a double blind, randomized, controlled trial in which they administered allogeneic umbilical cord blood cells potentiated with recombinant human erythropoietin (rhEPO) in CP patients. They observed improvement in motor and cognitive dysfunction in children with CP, accompanied by structural and metabolic changes in the brain. [70]

Papadopoulos et al administered autologous umbilical cord blood cells in 2 children diagnosed with spastic diplegic CP. They found that this therapy was safe, feasible and led to functional improvements in children which was seen by the change in GMFCS. [71]

Li et al, transplanted autologous bone marrow mesenchymal cells in an 11 year old CP case with visual impairment. On six month follow up, he could walk better and his vision

had improved significantly. These findings were supported by the electrophysiological examinations. [72]

Jensen et al recently published a study wherein a 2 ½ year old boy received autologous umbilical cord blood mononuclear cells intravenously. At 2-months follow-up the boy's motor control improved, spastic paresis was largely reduced, and eyesight was recovered, as did the EEG. He smiled when played with, was able to sit and to speak simple words. At 40 months, independent eating, walking in gait trainer, crawling, and moving from prone position to free sitting were possible, and there was significantly improved receptive and expressive speech competence (four-word sentences, 200 words). This suggested that autologous cord blood transplantation could be a treatment alternative for cerebral palsy. [73]

Wang et al reported a case of a 5-year old girl with CP who underwent umbilical cord mesenchymal stem cells (MSCs) transplantation. She was treated with multiple times of intravenous and intrathecal administration of MSCs derived from her young sister and was followed up for 28 months. The gross motor dysfunction was improved. Immunity was enhanced, physical strength improved along with speech and comprehension. [74]

Purandare et al, reported a case of cerebral palsy who was administered with autologous bone marrow mononuclear cells. On follow up, they recorded a significant improvement in motor, sensory, cognitive, and speech. Bowel and bladder control was also achieved. On the GMFCS-E&R level, the patient was promoted from grade III to I. Hence, concluding that intrathecal infusion of autologous BMMNCs is feasible, effective, and safe in CP patients. [75]

In our previously published cases of cerebral palsy, one was with comorbid intellectual disability [76] while the other one was without any comorbidity. [77] These cases were administered with autologous bone marrow mononuclear cells intrathecally. Six months after the treatment, both cases showed significant functional outcomes which was supported by improvement in PET CT scan.

### 3.1. Ongoing trials

Currently, there are five clinical trials on stem cell therapy for cerebral palsy registered in [clinicaltrials.gov](http://clinicaltrials.gov). [<http://clinicaltrials.gov/>]

2 studies are from India studying the safety and efficacy of bone marrow MNCs in cerebral palsy in children below 15 years. One of the studies is a combination of phase 1 and phase 2 while the other is a combination of phase 2 and phase 3.

2 studies are from Iran, one evaluating the side effects of bone marrow derived CD133 cells transplantation in cerebral palsy patients and the other studying the safety of multiple intrathecal injections of bone marrow derived CD133 cells.

A study from USA is based on evaluating the safety and effectiveness of a single, autologous, cord blood stem cell infusion for the treatment of cerebral palsy in children. It is a randomized, controlled, blind, crossover study

#### **4. Administration of autologous bone marrow derived mononuclear cells in children with cerebral palsy.**

Sharma et al, carried out a study on 71 children, wherein they administered 20 cases of cerebral palsy with autologous bone marrow mononuclear cells, intrathecally. [78] These cases included dystonic and spastic CP. Symptoms commonly observed in them were delayed milestones, spasticity, motor impairment, ambulation deficits, cognitive impairment, swallowing and speech problems etc.

Autologous bone marrow MNCs were selected as they are easily obtainable, safe and do not involve any ethical issues. As discussed earlier, intrathecal route of administration is a minimally invasive, safe and an effective procedure as compared to other routes. Studies have also proved that a mixture of cells exhibits more benefits as compared to a single sub fraction of cells. [79] Hence, we chose to carry out intrathecal autologous BMMNC transplantation.

The patients were administered Granulocyte Colony Stimulating Factor (GCSF), 48 hours and 24 hours before the harvest and transplantation of BMMNC. On the day of the transplantation, bone marrow was aspirated under general anesthesia in the operation theatre with aseptic precautions. Approximately, 100 ml of bone marrow (varying between 80 ml and 100 ml, based on the age and body weight) was aspirated from the region of anterior superior iliac spine using the bone marrow aspiration needle and collected in the heparinized tubes.

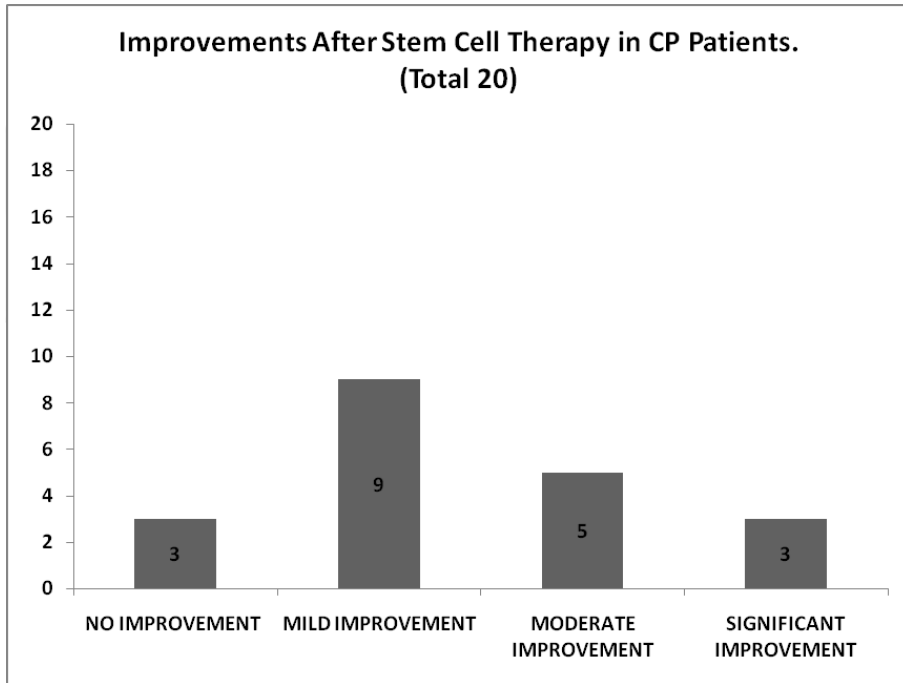
The aspirate was then transferred to the laboratory where the mononuclear cells were separated by the density gradient method. CD34+ counting was done by Fluorescence activated cell sorting (FACS). The MNCs were checked for viability (Average viability count was found to be 97%).

The separated autologous BMMNCs were immediately injected on the same day, intrathecally using an 18G Touhy needle and epidural catheter at the level between fourth and fifth lumbar vertebrae. The average numbers of cells injected were  $8.19 \times 10^7$ . Simultaneously 20mg/kg body weight methyl prednisolone in 500 ml Ringer Lactate was given intravenously to enhance survival of the injected cells. Patient was monitored for any adverse events.

On mean follow up of 15 months  $\pm$  1 month post stem cell administration, improvement was observed in 85% cases. [Figure 3] Significant improvement was observed in spasticity, neck holding, drooling of saliva, muscle strength in upper and lower limbs, sitting and standing balance, gross and fine motor activities, speech, swallowing, ambulation, and cognition. There was also a reduction in dystonic movements. No major adverse events were recorded. Some minor side effects such as headache, nausea and vomiting were experienced by few children who were self-limiting (resolved within a week) and treated with medications. The improvements in these patients sustained even after the follow up period of the study. None of them showed any deterioration on the GMFCS [78]

We are also currently conducting a clinical study to assess the efficacy of autologous BMMNC in 64 patients with CP. These patients are being treated with a combination of cell therapy and rehabilitation. The unpublished data analysis have shown preliminary results as improvement

in oromotor skills, speech, neck holding, sitting, standing and walking balance and significant reduction in muscular tone and dystonic movements. These changes were observed in all types of cerebral palsy over 6 months with varied follow up periods. [Figure 4,5,6]



**Figure 3.** Graph demonstrating overall improvements in CP patients after stem cell therapy.

Percentage improvement noted in patients of diplegic cerebral palsy was as follows. Oromotor skills (75%), speech (64%), neck holding (100%), Sitting balance (67%), standing balance (67%), walking balance (67%), ambulation (30%), leg movements (54%), overhead movements (38%), distal hand movements (69%), upper limb spasticity (38%), Lower limb spasticity (38%), trunk muscle tone (36%), trunk dissociation (30%)

Percentage improvement noted in patients of quadriplegic cerebral palsy was as follows. Oromotor skills (58%), speech (40%), neck holding (94%), Sitting balance (48%), standing balance (27%), walking balance (21%), ambulation (13%), involuntary movements (25%), upper limb spasticity (51%), Lower limb spasticity (50%), trunk muscle tone (36%)

Percentage improvement noted in patients with other types of cerebral palsy was as follows. Oromotor skills (55%), speech (55%), neck holding (40%), Sitting balance (45%), standing balance (50%), walking balance (27%), involuntary movements (9%), upper limb spasticity (22%), lower limb spasticity (14%), dystonia of upper limbs (50%), dystonia of lower limbs (100%), dystonia of the trunk (50%)

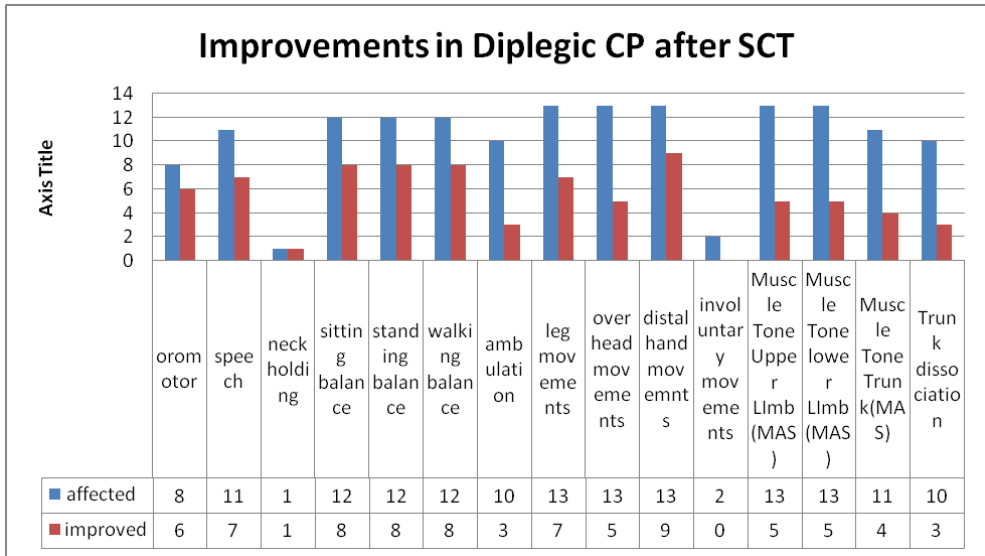


Figure 4. Graph demonstrating improvements in Diplegic CP patients after stem cell therapy

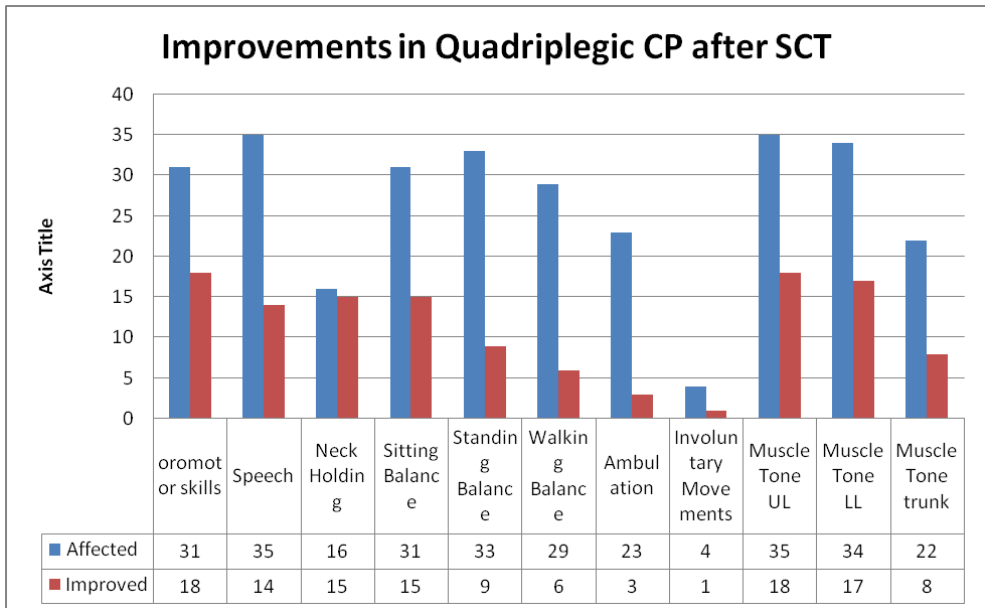
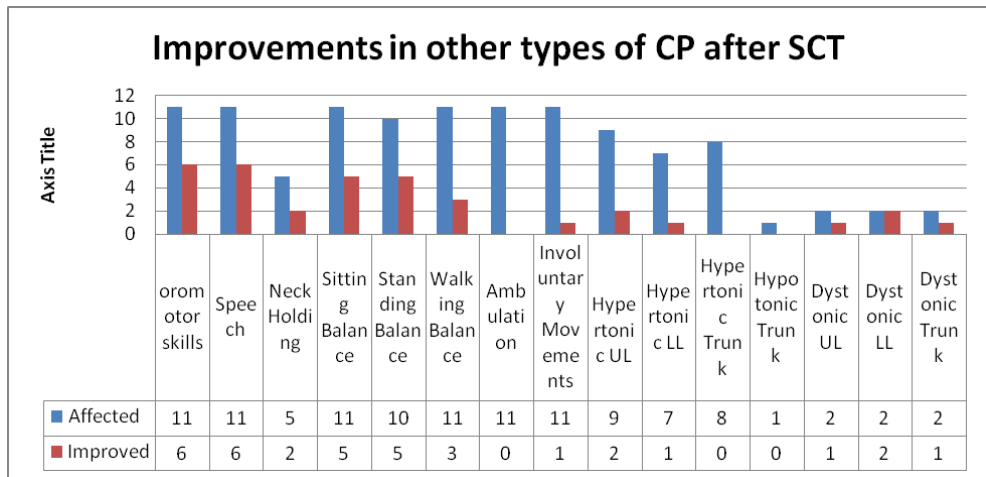


Figure 5. Graph demonstrating improvements in Quadriplegic CP patients after stem cell therapy



**Figure 6.** Graph demonstrating improvements in other types of CP patients after stem cell therapy

## 5. Objective imaging evidence

Various clinical outcome measures have been devised to measure changes in sensory, motor, cognitive, perceptual and Behaviour functions in CP. [80] It is however important to understand the underlying mechanisms behind these changes.

MRI scans not only help reveal the underlying pathology of CP, but it also correlates with the clinical findings. [81] It has been observed that, clinical trials using MRI as a primary outcome measure failed to fully identify the effects of the therapy on clinical measures. [82] MRI shows the structural malformations and grey and white matter lesions, these are only suggestive of underlying tissue mechanisms; but MRI is not sensitive to measure the changes at cellular level. Principle mechanisms underlying the benefits of cellular therapy are the changes brought about in the microenvironment of cells reducing cell necrosis, ischemia and hypoxia. These changes therefore cannot be measured on a plane MRI and hence it is not a sensitive tool to monitor the effects of stem cell therapy. Functional neuroimaging on the other hand may be an appropriate option to monitor the finer changes at cellular level.

The basic principle underlying the functional neuroimaging of the brain is that the cerebral blood flow and metabolism is associated with neuronal activity. [83] Stem cell therapy aims to modulate neuronal tissue function in the patients of cerebral palsy, through various paracrine mechanisms. Measurement of the tissue function is therefore a preferred outcome measure to monitor the effects of cellular therapy.

Positron Emission Tomography – Computed Tomography (PET – CT) is one of the techniques of functional neuroimaging that measures the metabolism of the nervous tissue in terms of

Fluoro-deoxy glucose (FDG) uptake. FDG is a radioactive glucose analogue that undergoes glycolysis in the same manner as that of glucose. Once it has been metabolized to FDG – 6 – Phosphate it cannot be further metabolized and is trapped inside the cell due to the impermeability of the cell membrane for this molecule. With increased glycolysis higher concentration of FDG-6-phosphate is observed. Photons emitted by this radioactive isotope are then measured to identify concentration of FDG in the nervous tissue [84]. This is expressed as a ratio of the actual uptake and the calculated presumed uptake of FDG, standard uptake value [85]. Because of its ability to measure the finer changes in tissue metabolism, FDG PET-CT holds a great potential as a monitoring tool. [86,87]

PET-CT scan is performed following a standard protocol. Various guidelines are available for appropriate standardization, image acquisition and interpretation during PET-CT scanning. Dosage of the radioactive dye is calculated based on the age and weight of the patient. Calculated units are then administered systemically 30 minutes before scanning. [88].

FDG, chemically expressed as  $^{18}\text{F}$ -FDG is radionuclide and therefore special safety concerns with its use need to be address. The primary safety concern is exposure to radiation. Incidence of developing any side effect is negligible with the use of  $^{18}\text{F}$ -FDG PET-CT. The half-life of  $^{18}\text{F}$ -FDG is 109.8 minutes and is excreted via urine. The tissue metabolism of  $^{18}\text{F}$ -FDG is the same in adult and children and the dose administered in children is “as low as reasonably achievable”. Various adjustments with regards to scanning technology and measurement period are made to enhance the quality of the image with the administered dose [89]. PET-CT is sensitive to measure the cellular changes and it is a standardized imaging modality which makes it a good monitoring tool to assess the effects of cellular therapy.

In our previous case studies involving cerebral palsy patients treated with autologous bone marrow derived mononuclear cells (BMMNCs), the clinical outcome was correlated with changes in the PET scan. In one case of a 20 year old CP patient with co morbid intellectual disability, a repeat PET-CT scan showed significant increase in the FDG uptake in various affected areas of the brain, which correlated with the clinical improvement in social behavior, balance and motor control. However the MRI remained unchanged (76).

In another case of a 2 year old child with cerebral palsy, we observed similar correlation of clinical improvement with the PET-CT changes in metabolism. (77) Six months following cellular therapy she developed good neck control along with improvement in balance and speech. These clinical changes were synonymous with the increased FDG uptake in the bilateral mesial temporal structures, right basal ganglia, frontal, parietal, temporal and occipital lobes.

Functional MRI is also one of the emerging techniques to study the functional outcome of the intervention. The technique of fMRI is based on Blood oxygenation level dependent (BOLD) contrast between rest and activated states of human brain. (90) Activation of neuronal tissue leads to increased metabolism and increased oxygen demands that have a twofold effect of greater oxygen extraction and increased cerebral blood flow; both of which result in higher BOLD signals than that of resting tissue. In ischemic tissues the blood flow–metabolism couple is impaired. Stem cells enhance angiogenesis, increasing the cerebral blood flow. Hence, fMRI



may be effectively used to monitor the therapeutic outcome of stem cell therapy and should be studied further. [91]

## 6. Role of rehabilitation in combination with stem cell therapy

For a long time, rehabilitation has been the standard approach for cerebral palsy. The goal of rehabilitation in cerebral palsy is to develop coordination, build strength, improve balance, maintain flexibility, optimize physical functions, manage spasticity and maximize independence. Rehabilitation is multidisciplinary. Various therapeutic regimens aim to enhance particular clinical, functional and psychosocial consequences of CP. Physiotherapy, makes use physical modalities to muscle spasticity, increase flexibility, balance and co-ordination, build strength and enhance function. Physiotherapists also prescribe different assistive devices to gain higher functionality. Multiple medical and surgical regimens are also instituted to deal with these physical impairments. Botox injections are most commonly used to reduce spasticity of the muscles, but the effects are short lived. A variety of surgical techniques are utilized to correct deformities.

Occupational therapy is focused at therapeutic regimens to improve cognitive abilities of the child and increase participation in activities of daily and social living. Children with CP most often present with poor oromotor control and speech disorders, speech therapy aims at correcting these impairments. Psychiatric and psychological intervention is aimed at patient and caregiver wellbeing. It helps to improve the quality of life by addressing co-morbid psychological disturbances and cognitive impairments.

All of the rehabilitative modalities face the fundamental limitation of inability to repair the damage to the nervous tissue. Some studies have defined minor improvements in motor and social skills. Wright and Nicholson and Sommerfeld et al have demonstrated that physical therapy alone does not show a consistent benefit in cerebral palsy. [92]

However, rehabilitation in combination with stem cell therapy may augment its benefits. Exercise helps in enhancing the cell proliferation and neurogenesis. [93] Increased mobilization of hematopoietic stem cells and erythropoietic progenitor cells (EPCs) to peripheral blood is observed post exercise. It also increases angiogenesis and oxygen supply to the brain thereby improving the cognitive function. [94,95,96]. Regular exercise induces suppression of pro-inflammatory cytokines and up regulation of anti-inflammatory cytokines in various tissues of the body including brain. [97,98,99] One of the key mechanisms for homing of bone marrow mononuclear stem cells is the chemokine stromal derived factor -1 / CXCR4+ receptor pathway, exercise has also been found to up regulate expression of CXCR4+ receptors in ischemic tissue ensuring enhanced homing of stem cells. In addition, mobilization of stem cells, enhanced homing, improved angiogenesis exercise also exerts immunomodulatory effects. [97] Benefits of regular exercise resonate with the cellular mechanisms of stem cell therapy and therefore it augments the therapeutic potential of stem cell therapy. Exercise and rehabilitation has a synergistic effect for the benefits of cell transplantation. [100]

## 7. Future direction

Stem cell therapy for cerebral palsy still remains in its infant stage. Although cellular therapy for cerebral palsy has moved from the preclinical studies to bedside therapy; evidence remains inconclusive regarding multitude of variables. These variables are pertaining to cerebral palsy and cellular therapy.

Cerebral palsy is a heterogeneous group of disorders. This inherently reduces the generalizability of the findings. Pre-clinical models of effects of cellular therapy in cerebral palsy are far from the ideal state and show benefits only in acute injury. Majority of the human application of stem cells in cerebral palsy is for individuals who already have established pathology, hence at a chronic stage. Animal models of chronic injury are therefore required to study the efficacy and mechanism of action of stem cells. The individuals suffering from cerebral palsy are from various age groups, and present with varied kinds and severities of clinical manifestations; there is only a limited evidence about which of these groups will benefit the most from cellular therapy.

Only preliminary evidence using basic research methodologies is available for the effects of cellular therapy in humans. Various factors limit the methodological robustness of the current trials. There are limited controlled trials in humans with cerebral palsy. We require more double blind, randomized, multicenter controlled clinical trials to prove the safety and feasibility of stem cells. The evidence available is heterogeneous in methodology, patient population, outcome measures and cellular therapy provided. Stem cells provide their beneficial effects through numerous mechanisms; it is difficult to underpin the exact mechanism of action of stem cells. Types, sources and numbers of cells administered, frequency of transplantation, time of transplantation are concerns which require attention imperatively. It is important to not only conduct more trials but also to standardize research protocols to allow comparison. Comparative studies will help in establishing the most effective cell based therapy for cerebral palsy.

Apart from these issues, development and validation of outcome measures to obtain evidence of the efficacy of intervention is very important. Different scales, monitoring tools need to be standardized. Modalities should be developed to study the effect of cell transplantation at a cellular level. Outcomes that can successfully assess these cellular changes are measuring the serum, plasma and cerebrospinal fluid biomarkers, which are invasive. Less invasive modalities would be functional imaging techniques. PET-CT scan has been used as an outcome to assess the effects of cellular therapy however it is required to further explore its various components in depth. fMRI also provides insights regarding the changes at cellular level however there is no evidence of its use in monitoring the changes post cellular therapy. It is therefore necessary to explore how functional imaging can provide us a better understanding of the cellular mechanisms.

## 8. Conclusion

Stem cell therapy has been extensively studied but still needs to be standardized before it becomes a definitive treatment modality. Autologous BMMNCs are safe and feasible option

but their effectiveness needs more clinical trials. Other types of stem cells need to establish safety and efficacy. Though not a cure, stem cell therapy has emerged as a novel therapeutic option to improve the quality of life.

## Author details

Alok Sharma<sup>1\*</sup>, Hemangi Sane<sup>2</sup>, Nandini Gokulchandran<sup>1</sup>, Prerna Badhe<sup>1</sup>, Pooja Kulkarni<sup>2</sup> and Amruta Paranjape<sup>3</sup>

\*Address all correspondence to: [alok276@gmail.com](mailto:alok276@gmail.com)

1 Department of Medical Service and Clinical Research, Neurogen Brain and Spine Institute, Mumbai, India

2 Department of Research and Development, Neurogen Brain and Spine Institute, Mumbai, India

3 Department of Neurorehabilitation, Neurogen Brain and Spine Institute, Mumbai, India

## References

- [1] [http://www.nobelprize.org/nobel\\_prizes/medicine/laureates/2012/press.html](http://www.nobelprize.org/nobel_prizes/medicine/laureates/2012/press.html)
- [2] Cajal SRY. Degeneration and regeneration of the nervous system. In: May RM, editor. Trans. London: Oxford University Press; 1928
- [3] Panteliadis CP., Strassburg HM. Cerebral Palsy: Principles and Management. Stuttgart, NY: Georg Thieme; 2004
- [4] Potten CS, Loeffler M. Stem cells: attributes, cycles, spirals, pitfalls and uncertainties. Lessons for and from the crypt. *Development*. 1990;110(4):1001-20
- [5] Lakshmipathy U, Verfaillie C. Stem cell plasticity. *Blood Rev*. 2005;19(1):29-38.
- [6] Evans M, Kaufman M. Establishment in culture of pluripotent cells from mouse embryos. *Nature* 1981; 292: 154–156.
- [7] De Wert G, Christine M. Human embryonic stem cells: research, ethics and policy. *Human reproduction* 2003; 18(4): 672-682.
- [8] Ben-David U, Benvenisty N. The tumorigenicity of human embryonic and induced pluripotent stem cells. *Nat Rev Cancer*. 2011;11:268-77
- [9] Pappa KI, Anagnou NP. Novel sources of fetal stem cells: where do they fit on the developmental continuum? *Regen Med*. 2009;4(3):423-33

- [10] Ilancheran S, Michalska A, Peh G, Wallace EM, Pera M, Manuelpillai U. Stem cells derived from human fetal membranes display multilineage differentiation potential. *Biol Reprod.* 2007;77(3):577-88.
- [11] Parsons C, Barbara S, Dean K. Susceptibility of human fetal mesenchymal stem cells to Kaposi sarcoma-associated herpesvirus. *Blood* 2004; 104(9): 2736-2738
- [12] Newcomb JD, Willing AE, Sanberg PR. Umbilical cord blood cells. *Methods Mol Biol.* 2009;549:119-36.
- [13] Stanevsky A, Goldstein G, Nagler A. Umbilical cord blood transplantation: pros, cons and beyond. *Blood Rev.* 2009;23(5):199-204.
- [14] Moise K.J. Umbilical cord stem cells. *Obstetrics and Gynecology.* 2005; 106(6), 1393-1407
- [15] Chik KW, Chan PK, Li CK, et al. Human herpesvirus-6 encephalitis after unrelated umbilical cord blood transplant in children. *Bone Marrow Transplantation.* 2002;99:991-994
- [16] El-Cheikh J, Fürst S, Casalonga F, Crocchiolo R, Castagna L, et al. JC Virus Leuko-Encephalopathy in Reduced Intensity Conditioning Cord Blood Transplant Recipient with a Review of the Literature. *Mediterr J Hematol Infect Dis.* 2012;4(1):e2012043
- [17] Robbins RD, Prasain N, Maier BF, et al. Inducible pluripotent stem cells: not quite ready for prime time? *Current Opinion in Organ Transplantation.* 2010;15:61-67.
- [18] Kim SU, de Vellis J. Stem cell-based cell therapy in neurological diseases: a review. *Journal of Neuroscience Research,* 2009; 87(10): 2183-2200
- [19] Trehwhitt, Kathryn G. Bone marrow aspiration and biopsy: collection and interpretation. *Oncology nursing forum.* Vol. 28. No. 9. Oncology nursing society, 2001.
- [20] Bianco P, Riminucci M, Gronthos S, Robey PG, Bone marrow stromal stem cells: nature, biology, and potential applications. *Stem Cells* 2001; 19(3):180-192
- [21] Bonilla S, Alarcón P, Villaverde R, Aparicio P, Silva A, Martínez S. Haematopoietic progenitor cells from adult bone marrow differentiate into cells that express oligodendroglial antigens in the neonatal mouse brain. *Eur J Neurosci.* 2002;15(3):575-82.
- [22] Zhao LR, Duan WM, Reyes M, Keene CD, Verfaillie CM, Low WC. Human bone marrow stem cells exhibit neural phenotypes and ameliorate neurological deficits after grafting into the ischemic brain of rats. *Exp Neurol.* 2002;174(1):11-20.
- [23] Boxall S, Jones E. Markers for Characterization of Bone Marrow Multipotential Stromal Cells. *Stem Cells International,* vol. 2012, Article ID 975871, 12 pages, 2012.
- [24] Yoo J, Kim HS, Hwang DY. Stem cells as promising therapeutic options for neurological disorders. *J Cell Biochem.* 2013;114(4):743-53.

- [25] Orozco L, Munar A, Soler R, Alberca M, Soler F, Huguet M, Sentís J, Sánchez A, García-Sancho J. Treatment of Knee Osteoarthritis With Autologous Mesenchymal Stem Cells: A Pilot Study. *Transplantation*. 2013 ;95(12):1535-1541.
- [26] Dobrowolski S, Lepski G. Stem cells in traumatic brain injury. *Am. J. Neurosci* 2013; 4: 13-24.
- [27] Ciara T, Case C. Transplanted Mesenchymal Stem Cells Aid the Injured Brain Through Trophic Support Mechanisms. *Stem Cells and Cancer Stem Cells, Volume 4*. Springer Netherlands, 2012. 297-303.
- [28] Zuk PA, Zhu M, Mizuno H, Huang J, Futrell JW, Katz AJ, Benhaim P, Lorenz HP, Hedrick MH. Multilineage cells from human adipose tissue: implications for cell-based therapies. *Tissue Eng*. 2001;7(2):211-28.
- [29] Kim M, Kim I, Lee SK, Bang SI, Lim SY. Clinical trial of autologous differentiated adipocytes from stem cells derived from human adipose tissue. *Dermatol Surg*. 2011;37(6):750-9.
- [30] Nakama K, Choi SW, Yang PS, Song KC, Ko MS, Jo JY, Ra JC. Therapy of autologous human adipose tissue-derived mesenchymal stem cells for the cerebral palsy: a case report. 2012; 1(1)
- [31] Gronthos S, Mankani M, Brahimi J, Robey PG, Shi S. Postnatal human dental pulp stem cells (DPSCs) in vitro and in vivo. *Proc Natl Acad Sci USA* 2000;97:13625-13630.
- [32] Jamal M, Chogle S, Goodis H, Karam S. M. Dental stem cells and their potential role in regenerative medicine. *J Med Sci*. 2011 4(2), 53-61.
- [33] Arthur A, Rychkov G, Shi S, Koblar SA, Gronthos S. Adult human dental pulp stem cells differentiate toward functionally active neurons under appropriate environmental cues. *Stem Cells* 2008;26: 1787–1795.
- [34] Patel AN, Park E, Kuzman M, Benetti F, Silva F J, Allickson J G. Multipotent menstrual blood stromal stem cells: isolation, characterization, and differentiation. *Cell transplantation*. 2008;17(3), 303-311.
- [35] Bender JG, Unverzagt KL, Walker DE, Lee W, Epps DEV, Smith DH, Stewart CC, Bik To L: Identification and comparison of CD34-positive cells and their subpopulations from normal peripheral blood and bone marrow using multicolor flow cytometry. *Blood* 1991;77:2591-2596
- [36] Lim JY, Jeong CH, Jun JA, Kim SM, Ryu CH, Hou Y, Oh W, Chang JW, Jeun SS. Therapeutic effects of human umbilical cord blood-derived mesenchymal stem cells after intrathecal administration by lumbar puncture in a rat model of cerebral ischemia. *Stem Cell Res Ther*. 2011;2(5):38.
- [37] Mehta T, Feroz A, Thakkar U, Vanikar A, Shah V, Trivedi H. Subarachnoid placement of stem cells in neurological disorders. *Transplant Proc*. 2008;40(4):1145-7.

- [38] Fischer UM, Harting MT, Jimenez F, Monzon-Posadas WO, Xue H, Savitz SI, Laine GA, Cox CS Jr. Pulmonary passage is a major obstacle for intravenous stem cell delivery: the pulmonary first-pass effect. *Stem Cells Dev.* 2009;18(5):683-92)
- [39] Kang SK, Lee DH, Bae YC, Kim HK, Baik SY, Jung JS. Improvement of neurological deficits by intracerebral transplantation of human adipose tissue-derived stromal cells after cerebral ischemia in rats. *Exp Neurol* 2003, 183:355-366
- [40] Nakamura Y, Okudera T, Hashimoto T: Vascular architecture in white matter of neonates: Its relationship to periventricular leukomalacia. *J Neuropathol Exp Neurol* 1994;53:582-589
- [41] Takashima S, Tanaka K: Development of cerebrovascular architecture and its relationship to periventricular leukomalacia. *Arch Neurol* 1978; 35:11-16
- [42] Volpe JJ: Neurobiology of periventricular leukomalacia in the premature infant. *Pediatr Res* 2001;50:553-562
- [43] Hagel C, Dimitrios S. Neuropathology of cerebral palsy. *Cerebral Palsy: Principles And Management* (2004): 49.
- [44] Back SA, Rivkees SA. Emerging concepts in periventricular white matter injury. *Semin Perinatol.* 2004;28(6):405-14.
- [45] Skaper SD, Giusti P, Facci L. Microglia and mast cells: two tracks on the road to neuroinflammation. *FASEB J.* 2012;26(8):3103-17.
- [46] Mundkur N. Neuroplasticity in children. *The Indian Journal of Pediatrics* 2005; 72(10):855-857
- [47] Goldman SA. Progenitor Cell-Based Treatment of the Pediatric Myelin Disorders. *Arch Neurol.* 2011;68(7):848-856.
- [48] Alvarez P, Carrillo E, Vélez C, Hita-Contreras F, Martínez-Amat A, Rodríguez-Serrano F, Boulaiz H, Ortiz R, Melguizo C, Prados J, Aránega A. Regulatory systems in bone marrow for hematopoietic stem/progenitor cells mobilization and homing. *Biomed Res Int.* 2013;2013:312656.
- [49] Gnecci M, Zhang Z, Ni A, Dzau, VJ. Paracrine mechanisms in adult stem cell signaling and therapy. *Circulation research*, 2008; 103(11), 1204-1219.
- [50] Daadi MM, Davis AS, Arac A, Li Z, Maag AL, Bhatnagar R, Jiang K, Sun G, Wu JC, Steinberg GK. Human neural stem cell grafts modify microglial response and enhance axonal sprouting in neonatal hypoxic-ischemic brain injury. *Stroke.* 2010;41(3): 516-23
- [51] Sharma S, Yang B, Strong R, Xi X, Brenneman M, Grotta JC, Aronowski J, Savitz SI. Bone marrow mononuclear cells protect neurons and modulate microglia in cell culture models of ischemic stroke. *J Neurosci Res.* 2010;88(13):2869-76.

- [52] Brenneman M, Sharma S, Harting M, Strong R, Cox CS Jr, Aronowski J, Grotta JC, Savitz SI. Autologous bone marrow mononuclear cells enhance recovery after acute ischemic stroke in young and middle-aged rats. *J Cereb Blood Flow Metab.* 2010;30(1):140-9.
- [53] Bae SH, Kong TH, Lee HS, Kim KS, Hong KS, Chopp M, Kang MS, Moon J. Long-lasting paracrine effects of human cord blood cells on damaged neocortex in an animal model of cerebral palsy. *Cell Transplant.* 2012;21(11):2497-515
- [54] Rosenkranz K, Tenbusch M, May C, Marcus K, Meier C. Changes in Interleukin-1 alpha serum levels after transplantation of umbilical cord blood cells in a model of perinatal hypoxic-ischemic brain damage. *Ann Anat.* 2013;195(2):122-7.
- [55] Wasielewski B, Jensen A, Roth-Härer A, Dermietzel R, Meier C. Neuroglial activation and Cx43 expression are reduced upon transplantation of human umbilical cord blood cells after perinatal hypoxic-ischemic injury. *Brain Res.* 2012;1487:39-53
- [56] Meier C, Middelani J, Wasielewski B, Neuhoff S, Roth-Härer A, Gantert M, Dinse HR, Dermietzel R, Jensen A. Spastic paresis after perinatal brain damage in rats is reduced by human cord blood mononuclear cells. *Pediatr Res.* 2006;59(2):244-9.
- [57] Wang XL, Zhao YS, Hu MY, Sun YQ, Chen YX, Bi XH. Umbilical cord blood cells regulate endogenous neural stem cell proliferation via hedgehog signaling in hypoxic ischemic neonatal rats. *Brain Res.* 2013;1518:26-35
- [58] Geissler M, Dinse HR, Neuhoff S, Kreikemeier K, Meier C. Human umbilical cord blood cells restore brain damage induced changes in rat somatosensory cortex. *PLoS One.* 2011;6(6):e20194.
- [59] Pimentel-Coelho PM, Magalhães ES, Lopes LM, deAzevedo LC, Santiago MF, Mendez-Otero R. Human cord blood transplantation in a neonatal rat model of hypoxic-ischemic brain damage: functional outcome related to neuroprotection in the striatum. *Stem Cells Dev.* 2010;19(3):351-8.
- [60] Tanaka N, Kamei N, Nakamae T, Yamamoto R, Ishikawa M, Fujiwara H, Miyoshi H, Asahara T, Ochi M, Kudo Y. CD133+ cells from human umbilical cord blood reduce cortical damage and promote axonal growth in neonatal rat organ co-cultures exposed to hypoxia. *Int J Dev Neurosci.* 2010;28(7):581-7.
- [61] Park KI, Himes BT, Stieg PE, Tessler A, Fischer I, Snyder EY. Neural stem cells may be uniquely suited for combined gene therapy and cell replacement: Evidence from engraftment of Neurotrophin-3-expressing stem cells in hypoxic-ischemic brain injury. *Exp Neurol.* 2006;199(1):179-90.
- [62] Qu SQ, Luan Z, Yin GC, Guo WL, Hu XH, Wu NH, Yan FQ, Qian YM. Transplantation of human fetal neural stem cells into cerebral ventricle of the neonatal rat following hypoxic-ischemic injury: survival, migration and differentiation. *Zhonghua Er Ke Za Zhi.* 2005;43(8):576-9.

- [63] Zheng T, Rossignol C, Leibovici A, Anderson KJ, Steindler DA, Weiss MD. Transplantation of multipotent astrocytic stem cells into a rat model of neonatal hypoxic-ischemic encephalopathy. *Brain Res.* 2006;1112(1):99-105.
- [64] Titomanlio L, Bouslama M, Le Verche V, Dalous J, Kaindl AM, Tsenkina Y, Lacaud A, Peineau S, El Ghouzzi V, Lelièvre V, Gressens P. Implanted neurosphere-derived precursors promote recovery after neonatal excitotoxic brain injury. *Stem Cells Dev.* 2011;20(5):865-79.
- [65] Chen A, Siow B, Blamire AM, Lako M, Clowry GJ. Transplantation of magnetically labeled mesenchymal stem cells in a model of perinatal brain injury. *Stem Cell Res.* 2010;5(3):255-66.
- [66] Yasuhara T, Matsukawa N, Yu G, Xu L, Mays RW, Kovach J, Deans RJ, Hess DC, Carroll JE, Borlongan CV. Behavioral and histological characterization of intrahippocampal grafts of human bone marrow-derived multipotent progenitor cells in neonatal rats with hypoxic-ischemic injury. *Cell Transplant.* 2006;15(3):231-8.
- [67] Webber DJ, van Blitterswijk M, Chandran S. Neuroprotective effect of oligodendrocyte precursor cell transplantation in a long-term model of periventricular leukomalacia. *Am J Pathol.* 2009;175(6):2332-42.
- [68] Luan Z, Liu W, Qu S, Du K, He S, Wang Z, Yang Y, Wang C, Gong X. Effects of neural progenitor cell transplantation in children with severe cerebral palsy. *Cell Transplant.* 2012; 21 Suppl 1:S91-8.
- [69] Chen G, Wang Y, Xu Z, Fang F, Xu R, Wang Y, Hu X, Fan L, Liu H. Neural stem cell-like cells derived from autologous bone mesenchymal stem cells for the treatment of patients with cerebral palsy. *J Transl Med.* 2013;11:21.
- [70] Min K, Song J, Kang JY, Ko J, Ryu JS, Kang MS, Jang SJ, Kim SH, Oh D, Kim MK, Kim SS, Kim M. Umbilical cord blood therapy potentiated with erythropoietin for children with cerebral palsy: a double-blind, randomized, placebo-controlled trial. *Stem Cells.* 2013;31(3):581-91.
- [71] Papadopoulos KI, Low SS, Aw TC, Chantarojanasiri T. Safety and feasibility of autologous umbilical cord blood transfusion in 2 toddlers with cerebral palsy and the role of low dose granulocyte-colony stimulating factor injections. *Restor Neurol Neurosci.* 2011; 29(1): 17-22.
- [72] Li M, Yu A, Zhang F, Dai G, Cheng H, Wang X, An Y. Treatment of one case of cerebral palsy combined with posterior visual pathway injury using autologous bone marrow mesenchymal stem cells. *J Transl Med.* 2012;10:100.
- [73] Jensen A, Hamelmann E. First autologous cell therapy of cerebral palsy caused by hypoxic-ischemic brain damage in a child after cardiac arrest-individual treatment with cord blood. *Case Rep Transplant.* 2013;2013:951827.
- [74] Wang L, Ji H, Zhou J, Xie J, Zhong Z, Li M, Bai W, Li N, Zhang Z, Wang X, Zhu D, Liu Y, Wu M. Therapeutic potential of umbilical cord mesenchymal stromal cells



- transplantation for cerebral palsy: a case report. *Case Rep Transplant.* 2013;2013:146347
- [75] Purandare C, Shitole DG, Belle V, Kedari A, Bora N, Joshi M. Therapeutic potential of autologous stem cell transplantation for cerebral palsy. *Case Rep Transplant.* 2012;2012:825289.
- [76] Sharma A, Sane H, Paranjape A, Gokulchandran N, Kulkarni P, Nagrajan A, Badhe P. Positron emission tomography-computer tomography scan used as a monitoring tool following cellular therapy in cerebral palsy and mental retardation-a case report. *Case Rep Neurol Med.* 2013;2013:141983
- [77] Sharma A, Kulkarni P, Sane H, Gokulchandran N, Badhe P, Lohia M, Mishra P. Positron Emission Tomography-Computed Tomography Scan Captures the Effects of Cellular Therapy in a Case of Cerebral Palsy. *J Clin Case Rep;* 2012, 2:13
- [78] Sharma A, Gokulchandran N, Chopra G, Kulkarni P, Lohia M, Badhe P, V.C.Jacob. Administration of autologous bone marrow derived mononuclear cells in children with incurable neurological disorders and injury is safe and improves their quality of life. *Cell Transplantation.* 2012; 21 Supp 1: S1–S12.
- [79] Pösel, Claudia, Karoline Moller, Wenke Frohlich, Isabell Schulz, Johannes Boltze, Daniel-Christoph Wagner. Density Gradient Centrifugation Compromises Bone Marrow Mononuclear Cell Yield. *PloS one.* 2012; 7(12):e50293.
- [80] Debuse D, Brace H. Outcome measures of activity for children with cerebral palsy: a systematic review. *Pediatr Phys Ther.* 2011;23(3):221-31
- [81] Bax M, Tydeman C, Flodmark O. Clinical and MRI Correlates of Cerebral Palsy: The European Cerebral Palsy Study. *JAMA.* 2006;296(13):1602-1608.
- [82] Li DK, Li MJ, Traboulosee A, Zhao G, Riddehough A, Paty D. The use of MRI as an outcome measure in clinical trials. *Adv Neurol.* 2006;98:203-26.
- [83] M. E. Raichle. Visualizing the mind. *Scientific American.* 1994; 270(4): 58–64
- [84] Pauwels EKJ, Ribeiro MJ, Stoot JHMB, McCready VR, Bourguignon M, Mazière B. FDG accumulation and tumor biology. *Nuclear Medicine and Biology.* 1998;25 (4): 317–322.
- [85] Thie JA. Understanding the standardized uptake value, its methods, and implications for usage. *Journal of Nuclear Medicine.* 2004; 45(9):1431–1434.
- [86] Sharma A, Gokulchandran N, Badhe P, Kulkarni P, Mishra P, Shetty A, Sane H. An Improved Case of Autism as Revealed by PET CT Scan in Patient Transplanted with Autologous Bone Marrow Derived Mononuclear Cells. *J Stem Cell Res Ther* 2013, 3:2
- [87] Sharma A, Gokulchandran N, Shetty A, Sane H, Kulkarni P, Badhe P. Autologous Bone Marrow Mononuclear Cells may be Explored as a Novel. Potential Therapeutic Option for Autism. *J Clin Case Rep* 2013, 3:7

- [88] Varrone A, Asenbaum S, Vander Borgh T, Booij J, Nobili F, Någren K, Darcourt J, Kapucu OL, Tatsch K, Bartenstein P, Van Laere K; European Association of Nuclear Medicine Neuroimaging Committee. EANM procedure guidelines for PET brain imaging using [18F]FDG, version 2. *Eur J Nucl Med Mol Imaging*. 2009;36(12):2103-10.
- [89] Devine CE, Mawlawi O. Radiation safety with positron emission tomography and computed tomography. *Semin Ultrasound CT MR*. 2010;31(1):39-45.
- [90] Ogawa S, Lee T, Nayak AS, Glynn P. Oxygenation-sensitive contrast in magnetic resonance image of rodent brain at high magnetic fields. *Magn Reson Med*. 1990;14:68-78.
- [91] Cao Y, D'Olhaberriague L, Vikingstad EM, Levine SR, Welch KM. Pilot study of functional MRI to assess cerebral activation of motor function after post stroke hemiparesis. *Stroke*. 1998;29(1):112-22.
- [92] Wright T, Nicholson J: Physiotherapy for the spastic child: An evaluation. *Dev Med Child Neurol* 15:146-163, 1973
- [93] vanPraag H, Christie BR, Sejnowski TJ, Gage FH. Running enhances neurogenesis, learning, and long-term potentiation in mice. *Proceeding of the National Academy of Sciences of the U S A*. 1999;96:13427-31
- [94] Colcombe S, Kramer AF. Fitness effects on the cognitive function of older adults: A metaanalytic study. *Psychol Sci*. 2003;14:125-30
- [95] Möbius-Winkler S, Hilberg T, Menzel K, Golla E, Burman A, Schuler G, Adams V. Time-dependent mobilization of circulating progenitor cells during strenuous exercise in healthy individuals. *J Appl Physiol*. 2009;107(6):1943-50.
- [96] Sandri M, Adams V, Gielen S, Linke A, Lenk K, Kränkel N, Lenz D, Erbs S, Scheinert D, Mohr FW, Schuler G, Hambrecht R. Effects of exercise and ischemia on mobilization and functional activation of blood-derived progenitor cells in patients with ischemic syndromes: results of 3 randomized studies. *Circulation*. 2005;111(25):3391-9.
- [97] Petersen AM, Pedersen BK. The anti-inflammatory effect of exercise. *J Appl Physiol*. 2005;98(4):1154-62.
- [98] Gielen S, Adams V, Möbius-Winkler S, Linke A, Erbs S, Yu J, Kempf W, Schubert A, Schuler G, Hambrecht R. Anti-inflammatory effects of exercise training in the skeletal muscle of patients with chronic heart failure. *J Am Coll Cardiol*. 2003;42(5):861-8.
- [99] Lin YS, Jan MS, Tsai TJ, Chen HI. Immunomodulatory effects of acute exercise bout in sedentary and trained rats. *Med Sci Sports Exerc*. 1995;27(1):73-8
- [100] Sharma A, Sane H, Badhe P, Kulkarni P, Chopra G, Lohia M, Gokulchandran N. Autologous Bone Marrow Stem Cell Therapy shows functional improvement in hemorrhagic stroke- a case study. *Indian Journal of Clinical Practice*, 2012;23(2):100-105