

PET - CT Scan Shows Decreased Severity of Autism after Autologous Cellular Therapy: A Case Report

Alok Sharma¹, Hemangi Sane², Nandini Gokulchandran¹, Prerna Badhe¹, Avantika Patil², Pooja Kulkarni^{2*} and Amruta Paranjape^{2,3}

¹Department of Medical Services and Clinical research, NeuroGen Brain and Spine Institution, Mumbai, India

²Department of Research and Development, NeuroGen Brain and Spine Institution, Mumbai, India

³Department of Neuro Rehabilitation, NeuroGen Brain and Spine Institution, Mumbai, India

*Corresponding author: Kulkarni P, Neurogen Brain and Spine Institute, Stem Asia Hospital and Research Centre, Plot No. 19, Sector 40, Navi Mumbai - 400706, India, Tel: +91 9920200400; E-mail: poojakul28@gmail.com

Rec date: February 01, 2016; Acc date: March 02, 2016; Pub date: March 09, 2016

Copyright: © 2016 Sharma A, et al. This is an open - access article distributed under the terms of the Creative Commons Attribution License, which permits unrestricted use, distribution, and reproduction in any medium, provided the original author and source are credited.

Abstract

PET - CT scan has been recently utilized to detect functional abnormalities in the brain. In autism, the MRI of brain is normal hence, functional neuroimaging techniques such as Positron Emission Tomography - Computer Tomography scan of the brain should be explored. Autism is a complex neurodevelopmental disorder affecting communication, behavior and socialization. Currently, available therapeutic approaches are aimed at symptomatic changes and do not target the core pathology in the brain of autism. Cell therapy has recently emerged as a promising treatment modality for autism. However, the effects of cell therapy need to be monitored by objective imaging. In this study, we present the case of a 6 year old boy with autism treated with intrathecal administration of autologous bone marrow mononuclear cells and monitored with Positron Emission Tomography - Computer Tomography scan. On regular follow up at 3 and 6 months, significant social, behavioral and communication improvements were observed. On outcome measures, the Indian Scale for Assessment of Autism score pre - intervention improved from 113 to 97, Functional Independence Measure improved significantly from 42 to 50 and Childhood Autism Rating Scale improved from 42.5 to 35.5. The severity of illness on Clinical Global Impression scale showed a change from a score of 5 (markedly ill) to 4 (moderately ill). Global improvement graded on the CGI scale was 2 (much improved). The efficacy index on Childhood Autism Rating Scale showed moderate therapeutic effect (score 5). Interestingly, Positron Emission Tomography - Computer Tomography comparisons at 6 months revealed improved metabolism of the previously hypometabolic areas of the brain which correlated well with clinical improvements. No adverse events were reported.

Keywords: Autism; Stem cell therapy; Bone marrow mononuclear cells; Autologous; Childhood autism Rating scale; Functional neuroimaging; Neurodevelopmental disorders

Introduction

Autism is a neurodevelopmental condition associated with a multifaceted presentation. This disorder is typically characterized by; deficits in communication and social reciprocity, hyperactivity, attention deficit, repetitive behavior and restricted interests. It usually begins in infancy and a definitive diagnosis is typically achieved at around 24 - 36 months [1]. According to the March 2014 report released by the United States Centres for Disease Control and Prevention, the prevalence of autism is an estimated 1 in 68 children [2]. This is a sharp increase from the previous report released in March 2012, which suggested the prevalence to be 1 in 88 children [2,3]. Various pathomechanisms have been implicated in the onset of autism which includes genetic factors, immune dysregulation and hypoperfusion. Current treatment options available for autism comprise of occupational therapy, behavior therapy, speech therapy, nutritional guidance and pharmacological treatment. However, these treatment options are directed towards achieving symptomatic changes in the affected individual but the underlying brain damage remains unaddressed.

In autism, MRI of brain is normal hence, functional neuroimaging techniques such as PET - CT scan of the brain should be explored to

study the effect of intervention. MRI of the brain gives information about the structural abnormalities of the brain. It does not record the cellular dysfunctions at the metabolic level. Whereas, PET CT scan uses biomarkers to record the metabolic changes at the cellular level [4]. Hence, PET CT scan brain is more sensitive in analyzing the effects of cell therapy on the function of the brain as compared to MRI. In this case report, 18 FDG PET CT scan has been used as a monitoring tool to study the effect of intrathecal administration of autologous bone marrow mononuclear cells (BMMNCs) in autism.

Herein, we present a case of autism that despite being treated with conventional medical therapies and treatments continued to experience major communication and behavioral deficits. Cell therapy has been widely studied and has shown to have potential as a novel treatment for various neurological disorders including autism [5-10]. These cells are safe, easily obtainable (involving less invasive techniques), non - teratogenic and have no ethical issues.

Materials and Methods

Case presentation

In this report, we present the case of a 6 year old boy with autism who, after showing limited response to other medical and rehabilitation interventions underwent autologous BMMNC transplantation. The boy was born by normal delivery at full term,

cried immediately after birth, with normal birth weight and had no neonatal complications. He had delayed developmental milestones and his speech was not developed. He was diagnosed with autism at the age of two years. No family history of autism was reported. He had normal vision and hearing. Clinical manifestations included hyperactivity with attention and concentration deficit. He also presented with stereotypical and self - stimulating behavior like finger counting, rocking and swinging. He had fair eye contact, but had difficulty maintaining it and had poor sitting tolerance. There was presence of self - injurious behavior like head banging along with behavioral issues like screaming and throwing things. His appetite was appropriate while there were occasional disturbances in his sleep patterns. Functionally, he was dependent for all Activities of Daily Living (ADLs), with a lack of complete toilet - training. He had poor social interaction and primarily used need based communication as his linguistic abilities were severely deficient. He exhibited abnormal emotional responses like irrelevant laughter, poor imitation skills, and inappropriate object use. He also exhibited sensory issues like hypersensitivity to noise and tactile hypersensitivity (preferred soft articles and liked the touch of rugs). He also presented with poor pragmatic skills, delayed response

time, poor proximal joint stability, hyporegistration for sensory stimulation and poor awareness of surroundings and body.

He scored 113 on Indian Scale for Assessment of Autism (ISAA), 42 on Functional Independence Measure (FIM) and 42.5 on Childhood Autism Rating Scale (CARS). Severity of illness on the Clinical Global Impression scale (CGI - I) was 5, categorizing him as markedly ill.

Magnetic Resonance Imaging (MRI) of the brain did not reveal any significant morphological abnormality. An electroencephalography (EEG) showed epileptiform activity from the bilateral centro - parietal regions, with no history of seizures. A Positron Emission Tomography-Computed Tomography (PET - CT) scan of the brain using the radioisotope 18 - F FDG (fluorodeoxyglucose) was performed on a Siemens Biograph HD MDCT with LSO detector technology. The PET - CT scans (Figure 1) revealed moderate to severe hypometabolism (reduced FDG uptake) in bilateral cerebellar hemispheres, along with mild hypometabolism in the bilateral thalami, amygdale, mesial temporal lobe. Hypermetabolism was observed in frontal lobe and middle frontal gyrus.

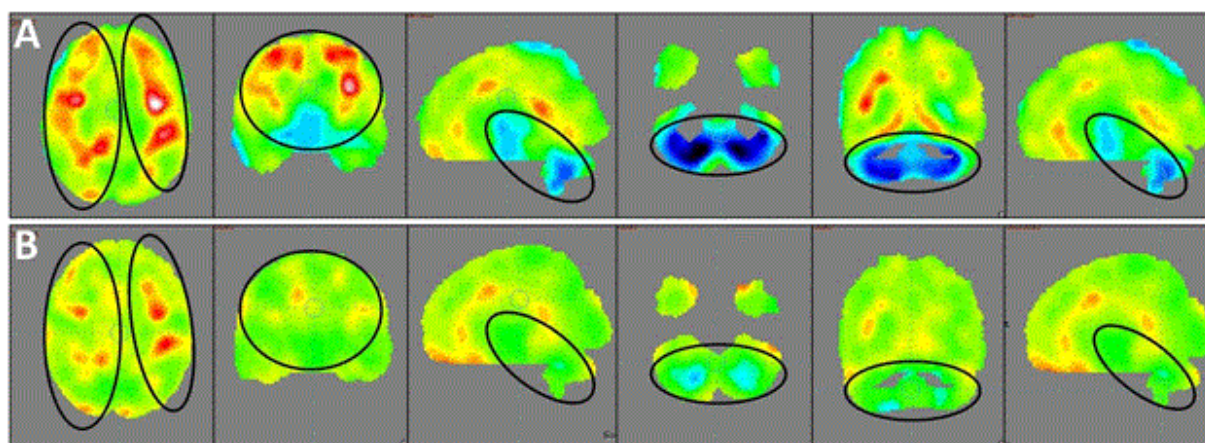


Figure 1: (A) PET - CT scans of the patient carried out pre - intervention. (B) Post - intervention PET - CT scans of the patient carried out after 6 months. Previously hypometabolic (hypofunctioning) brains areas depicted as blue areas show improved metabolism post - intervention, represented by green areas. Red areas representing hypermetabolism (hyperfunctioning) have improved to more normalized green areas post - intervention. The images reveal a balancing effect on overall brain metabolism

Procedure

Intrathecal administration of autologous BMMNCs was used as a treatment method. The rationale of this intervention is in accordance with the inclusion criterion of the World Medical Associations Helsinki declaration [11]. It has been reviewed and approved by the Institutional Committee for Stem Cell Research and Therapy (IC - SCRT). The parents of the patient were informed about the procedure and a duly filled informed consent form was obtained. Pre - procedure routine blood tests and chest x - ray were carried out to rule out active infection and assess fitness for anesthesia. MRI brain, PET CT scans brain and EEG was performed. 300 mcg of Granulocyte colony - stimulating factor (G - CSF) injections were administrated 72 hours and 24 hours prior to BMMNC transplantation, to stimulate CD34+ cells and increase their survival and multiplication [12]. A 100 ml volume of Bone marrow was aspirated from the iliac bone. The density gradient separation method was used to obtain Mononuclear Cells (MNCs). The MNCs were then evaluated for CD34+ by FACS analysis

and viable count was calculated and found to be about 98%. Approximately 2.35×10^8 MNCs were administered intrathecally immediately post separation, in the space between L4 - L5 using a lumbar puncture needle. 1 gm Methylprednisolone in 500 ml Ringer's Lactate (RL) was simultaneously injected intravenously to reduce local inflammation.

The patient also underwent rehabilitation therapy which included occupational therapy, psychological therapy and speech therapy. During rehabilitation sessions, effective motor learning strategies with task oriented training for real life environment were utilized and successful attainment of functional outcomes were achieved. The rehabilitation sessions were recorded and a CD with the exercises was given to the patient for home program, to be followed rigorously for next 6 months. No adverse events were reported throughout the course of the therapy.

Results

The patient showed significant improvements over the period of 6 months. At the follow up assessment after three months of receiving the therapy, the patients' hyperactivity had reduced along with a minimal improvement in sitting tolerance. Post - treatment, his awareness of surroundings, his understanding and eye contact had also improved.

On the follow up conducted six months after the therapy, all previously reported improvements were sustained. Hyperactivity had further reduced. Command following also improved and there was a considerable reduction in self-injurious behavior. His social interaction with other children improved. Reduction in tactile hypersensitivity was noted. He also developed efficiency in carrying out basic ADLs like eating. His ability to learn new tasks, problem solving and concept

forming improved; making it possible to perform tasks like finishing his homework. He could also perform coloring activities more efficiently.

The score on ISAA (Table 1) reduced from 113 (moderate autism) to 97 (mild autism) at six months. The score on CARS improved from 42.5 to 35.5. His FIM score also improved from 42 to 50. The severity of illness score on CGI - I reduced from 5 (markedly ill) to 4 (moderately ill). Global improvement on CGI - II scale suggested 'much improvement' with a score of 2. The efficacy index on CGI-III scale was scored as 5 which was suggestive of moderate therapeutic effect. Moderate therapeutic effect was characterized as definite improvement with partial remission of symptoms, without any side effects.

	Sub - components of ISAA	Score Pre - treatment	Score at 6 month follow up
A.	Social Relationship and Reciprocity	31	25
1	Has poor eye contact	2	1
2	Lacks social smile	4	1
3	Remains aloof	4	3
4	Does not reach out to others	3	3
5	Unable to relate to people	4	4
6	Unable to respond to social/environmental cues	5	4
7	Engages in solitary and repetitive play activities	3	3
8	Unable to take turns in social interaction	3	3
9	Does not maintain peer relationships	3	3
B	Emotional Responsiveness	10	9
1	Shows inappropriate emotional response	3	2
2	Shows exaggerated emotions	2	2
3	Engages in self - stimulating emotions	2	2
4	Lacks fear of danger	1	1
5	Excited or agitated for no apparent reason	2	2
C	Speech - Language and Communication	25	25
1	Acquired speech and lost it	5	5
2	Has difficulty in using non - verbal language or gestures to communicate	4	4
3	Engages in stereotyped and repetitive use of language	3	3
4	Engages in echolalic speech	1	1
5	Produces infantile squeals/unusual noises	2	2
6	Unable to initiate or sustain conversation with others	5	5
7	Uses jargon or meaningless words	2	2
8	Uses pronoun reversals	1	1
9	Unable to grasp pragmatics of communication	2	2

D	Behavior Patterns	24	20
1	Engages in stereotyped and repetitive motor mechanisms	4	3
2	Shows attachment to inanimate objects	4	4
3	Shows hyperactivity/restlessness	4	3
4	Exhibits aggressive behavior	4	3
5	Throws temper tantrums	4	4
6	Engages in self - injurious behavior	3	2
7	Insists on sameness	1	1
E	Sensory Aspects	14	10
1	Unusually sensitive to sensory stimuli	3	2
2	Stares into space for long periods of time	2	2
3	Has difficulty in tracking objects	2	1
4	Has unusual vision	1	1
5	Insensitive to pain	2	1
6	Responds to objects/people unusually by smelling, touching or tasting	4	3
F	Cognitive Component	9	8
1	Inconsistent attention and concentration	3	2
2	Shows delay in responding	3	3
3	Has unusual memory of some kind	2	2
4	Has 'savant' abilities	1	1
TOTAL		113	97

Table 1: Table showing the patients score on different sub - components of Indian Scale. for Assessment of Autism (ISAA) pre - intervention and at 6 months follow up post - intervention.

A PET - CT scan conducted 6 months post cellular therapy revealed improved metabolism in Amygdala, Cerebellum, Thalamus and Mesial temporal lobe bilaterally; along with improvements in hypermetabolic areas like Middle frontal gyrus, Frontal lobe and Parietal lobe. The mean standardized uptake values (SUVs), depicting improved metabolism in the different areas of brain (Table 2(A) and 2(B)).

Brain Areas	Mean SUV		Mean SUV		Mean SD		Mean SD		Correlating clinical functional improvements observed in patient
	(pre - therapy)		(post - therapy)		(pre - therapy)		(post - therapy)		
	Left	Right	Left	Right	Left	Right	Left	Right	
Amygdala	2.85	2.6	3.98	4.04	- 2.1	- 3.5	- 0.7	- 0.5	Social interaction, behaviour
Cerebellum	3.47	3.06	4.87	4.66	- 6.1	- 7.8	1.8	1.1	Balance, coordination,
Thalamus	3.5	3.37	4.99	5.11	- 1.8	- 2.5	0	0.3	Sensory interpretation, sleep and consciousness
Mesial temporal lobe	3.02	3.2	4.21	4.34	- 1.6	- 0.6	1.3	1.3	Social brain processing

Table 2 (A): Comparison of pre and post treatment SUV and SD values of previously hypometabolic areas in 18 FDG PET - CT scans and their correlation with clinical symptom improvements in the case study.

Brain Areas	Mean SUV		Mean SUV		Mean SD		Mean SD		Correlating clinical functional improvements observed in patient
	(pre - therapy)		(post - therapy)		(pre - therapy)		(post - therapy)		
	Left	Right	Left	Right	Left	Right	Left	Right	
Middle frontal gyrus	4.91	4.93	5.91	6.03	3.4	3.3	2.8	3	Decision - related processes, executive functions
Frontal lobe	4.7	4.62	5.68	5.69	3.6	3.3	2.9	3.2	Planning, initiation, problem solving, attention, emotions
Parietal Lobe	4.71	4.48	5.72	5.61	2.3	1.8	1.8	2.1	Integration of sensory information and language

Table 2 (B): Comparison of pre and post treatment SUV and SD values of previously hypermetabolic areas in 18 FDG PET - CT scans and their correlation with clinical symptom improvements in the case study.

Discussion

PET CT brain imaging was used as a monitoring tool to study the effect of intervention at the cellular level as other imaging studies like MRI do not give information about the function of the brain tissue and in most cases of autism it does not reveal any significant abnormality. PET CT utilizes 18 - FDG, a dye that is analogous to glucose. The dye is entrapped in the brain cells, which can then be measured on the CT scan giving a diagrammatic representation of the function of cells. Function of the brain cells is directly proportional to the glucose uptake and metabolism. Thus, hypofunctioning areas will depict reduced FDG uptake and hypometabolism; while hyperfunctioning areas will depict increased FDG uptake and hypermetabolism [13,14]. Uptake of the FDG dye by cells of a particular area is measured and a mean value of that area is calculated and recorded as mean SUV (Standard Uptake Value). These values are then compared to the control group values by the software and the standard deviation (SD) is calculated and recorded as SD value.

In this study, a comparative PET - CT investigation done after six months of intervention showed increased uptake of FDG in amygdala, cerebellum, thalamus and mesial temporal lobe which were previously hypometabolic or hypofunctioning. A reduced FDG uptake was observed in the middle frontal gyrus, calcarine fissure, as well as in the frontal and parietal lobes which were previously hypermetabolic or hyperfunctioning (Table 2(A) and 2(B)). These findings correlated with the clinical improvements recorded in the patient on follow up.

On follow up, significant clinical and functional improvements were observed and recorded on objective scales. The ISAA score reduced from 113 to 97 and correlated well with the observed clinical improvements. Significant improvements were observed in five out of six ISAA subcomponents; these were social relationship and reciprocity, emotional responsiveness, behavior patterns, sensory aspects and cognitive component. The CARS showed a significant improvement as the score reduced from 42 to 35.5, suggesting a shift from severe autism to mild - moderate autism. The child's FIM score also improved from 42 to 50. This change was supported by the boy's ability to become more independent in his ADLs. Severity of illness of the CGI scale showed an improvement from 5 (markedly ill) to 4 (moderately ill). Global improvement on CGI scale graded him with a score of 2 (much improved). The efficacy index on CGI was noted to be 5 i.e. moderate therapeutic effects. This indicates that there was decided improvement with partial remission of symptoms with no side effects.

Autologous BMMNCs have been extensively studied and shown to be a promising therapeutic approach to address the core neuropathology of autism. It has the potential to repair neural tissue damage at the molecular, functional and structural levels. These cells are a combination of hematopoietic cell populations such as CD34+ cells and non - hematopoietic cells like mesenchymal stem cells (MSCs), stromal cells and tissue specific progenitor cells [15]. The rationale behind this therapy lies in the knowledge that the functional effects of BMMNCs arise from a delicate balance between the beneficial effects of different cell types. These cells can be easily obtained and their safety and potency have been well defined with no ethical issues.

Inflammation, inflammatory response and immune activation have been strongly implicated in the pathogenesis of autism [3]. Several studies exploring this aspect have found abnormalities in the peripheral immune system, while related studies have revealed other immune disruptions involving activation of the innate neuroimmune system and microglial cells [16-18]. Evidence suggests that the function of the blood brain barrier (BBB), a crucial regulator of brain homeostasis, is altered in autism due to neuroinflammation, increased inflammatory cytokines and immune dysregulation in the brain [17,18]. An imbalance of various cytokines like IFN - γ and interleukins (ILs) has been reported in the peripheral blood, along with an increased activation of pathways involving Th1 and Th2 [19].

A crucial effect of BMMNCs is immunomodulation through an increase in anti - inflammatory TGF - β and IL - 10; along with an inhibition of pro - inflammatory cytokine production of TNF - α , IL - 1 β and INF - γ . They also show paracrine effects and induce angiogenesis by the production of vital growth factors like fibroblast growth factor (FGF2), vascular endothelial growth factor and ciliary neurotropic factor (CNTF). Immunomodulation counterbalances the dysregulated immune system and restores normal functioning by reducing neural damage [20].

Hypoperfusion has also been recognized as a major underlying pathology of autism. It causes abnormal neurotransmitter or metabolite accumulation and hypoxia, further causing neural tissue damage [17]. The severity of symptoms observed in autism is believed to be directly proportional to the degree of hypoperfusion. One of the important effects of BMMNCs is neoangiogenesis. This reduces hypoxia by improving clearance of toxic metabolites and perfusion [21,22].

The neuroanatomy studies in autism have revealed the involvement of the cerebellum, frontal lobes and mesial temporal lobe (amygdala)

along with an imbalance in the connectivity of the brain [23-25]. The imbalance in the excitation - inhibition pathways of neurons plays a crucial role in autism. A recent study suggests that during the development of an autistic brain, excitatory (glutamatergic) neurons remain unaffected while inhibitory (GABAergic) neurons increase. BMMNCs through its paracrine effect, neurorepair, synaptogenesis, axonal sprouting improves the neuronal connectivity and the excitatory - inhibitory balance [26,27].

Intrathecal administration of BMMNCs, a relatively less invasive procedure allows the cells to breach the BBB, migrate to and "home" into the affected brain areas through the CSF [28]. Since the intervention is autologous, BMMNCs avoid the risk of a rejection making it a safe and feasible therapeutic approach.

Hence, we hypothesize that these multitudes of reparative mechanisms restore the connectivity in the autistic brain resulting in clinical improvements. The improved cellular functions are reflected on the PET CT findings as a balancing effect of brain metabolism in autism.

Though a solitary case, the significant improvements with objective PET - CT findings demonstrate that autologous BMMNC transplantation may be a feasible and safe therapeutic approach in the treatment of autism. However, to ascertain the therapeutic benefits of cellular therapy in autism and to compare the benefits of different types of cells and different routes of administration; multicentre randomized controlled trials with larger sample size are necessary. PET - CT scan can be used as a more sensitive monitoring tool and outcome measure for assessing benefits of cellular therapy in combination with standard rehabilitation.

References

1. Autism and Developmental Disabilities Monitoring Network Surveillance Year 2008 Prevalence Investigators; Centres for Disease Control and Prevention (2012) Prevalence of autism spectrum disorders – Autism and Developmental Disabilities Monitoring Network, 11 sites, United States, 2010. *MMWR SurveillSumm* 63: 1-21.
2. Autism and Developmental Disabilities Monitoring Network Surveillance Year 2010 Prevalence Investigators; Centres for Disease Control and Prevention (2014) Prevalence of autism spectrum disorders – Autism and Developmental Disabilities Monitoring Network, 14 sites, United States, 2008. *MMWR SurveillSumm* 61: 1-19.
3. Samsam M, Ahangari R, Naser SA (2014) Pathophysiology of autism spectrum disorders: Revisiting gastrointestinal involvement and immune imbalance. *World Journal of Gastroenterology* 29: 9942-9951.
4. Schifter T, Hoffman JM, Hatten HP Jr, Hanson MW, Coleman RE, et al. (1994) Neuroimaging in infantile autism. *J Child Neurol* 9: 155-161.
5. Sharma A1, Gokulchandran N, Sane H, Nagrajan A, Paranjape A, et al. (2013) Autologous bone marrow mononuclear cell therapy for autism: an open label proof of concept study. *Stem Cells Int* 2013: 623875.
6. Sharma A, Gokulchandran N, Shetty A, Sane H, Kulkarni P, et al. (2013) Autologous Bone Marrow Mononuclear Cells may be Explored as a Novel Potential Therapeutic Option for Autism. *J Clin Case Rep* 3:282.
7. Sharma A, Gokulchandran N, Chopra G, Kulkarni P, Lohia M, et al. (2012) Administration of autologous bone marrow-derived mononuclear cells in children with incurable neurological disorders and injury is safe and improves their quality of life. *Cell Transplantation. Suppl* 1: S79-90.
8. Sharma A, Badhe P, Gokulchandran N, Kulkarni P, Mishra P, et al. (2013) An improved case of autism as revealed by PET CT scan in patient transplanted with autologous bone marrow derived mononuclear cells. *J Stem Cell Res Ther.* 139: 2.
9. Sharma A, Gokulchandran N, Sane H, Kulkarni P, Thomas N, et al. (2013) Intrathecal autologous bone marrow mononuclear cell transplantation in a case of adult autism. *Autism open access.*3:2
10. Bradstreet JJ, Sych N, Antonucci N, Klunnik M, Ivankova O, et al. (2014) Efficacy of fetal stem cell transplantation in autism spectrum disorders: an open-labeled pilot study. *Cell Transplant* 23 Suppl 1: S105-112.
11. Carlson RV, Boyd KM, Webb DJ (2004) The revision of the Declaration of Helsinki: past, present and future. *Br J Clin Pharmacol* 57: 695-713.
12. Petit I, Szyper-Kravitz M, Nagler A, Lahav M, Peled A, et al. (2002) G-CSF induces stem cell mobilization by decreasing bone marrow SDF-1 and up-regulating CXCR4. *Nat Immunol* 3: 687-694.
13. Chugani DC (2012) Neuroimaging and neurochemistry of autism. *Pediatr Clin North Am* 59: 63-73, x.
14. Galuska L, Szakáll S Jr, Emri M, Oláh R, Varga J, et al. (2002) [PET and SPECT scans in autistic children]. *Orv Hetil* 143: 1302-1304.
15. Brenes RA, Bear M, Jadlovec C, Goodwin M, Hashim P, et al. (2012) Cell-based interventions for therapeutic angiogenesis: review of potential cell sources. *Vascular* 20: 360-368.
16. Pardo CA, Vargas DL, Zimmerman AW (2005) Immunity, neuroglia and neuroinflammation in autism. *Int Rev Psychiatry* 17: 485-495.
17. Ichim TE, Solano F, Glenn E, Morales F, Smith L, et al. (2007) Stem cell therapy for autism. *J Transl Med* 5: 30.
18. Noriega DB, Savelkoul HF (2014) Immune dysregulation in autism spectrum disorder. *Eur J Pediatr* 173: 33-43.
19. Molloy CA, Morrow AL, Meinzen-Derr J, Schleifer K, Dienger K, et al. (2006) Elevated cytokine levels in children with autism spectrum disorder. *J Neuroimmunol* 172: 198-205.
20. Siniscalco D, Sapone A, Cirillo A, Giordano C, Maione S, et al. (2012) Autism spectrum disorders: is mesenchymal stem cell personalized therapy the future? *J Biomed Biotechnol* 2012: 480289.
21. Nakano Doi A, Nakagomi T, Fujikawa M, Nakagomi N, Kubo S et al. (2010) Bonemarrow mononuclear cells promote proliferation of endogenous neural stem cells through vascular niches after cerebral infarction. *Stem Cells* 28:1292-1302
22. Siniscalco D, Bradstreet J, Antonucci N (2012) The promise of regenerative medicine and stem cell research for the treatment of autism. *Journal of Regenerative Medicine* 1:1.
23. Amaral DG, Schumann CM, Nordahl CW (2008) Neuroanatomy of autism. *Trends Neurosci* 31: 137-145.
24. Hahamy A, Behrmann M, Malach R (2015) The idiosyncratic brain: distortion of spontaneous connectivity patterns in autism spectrum disorder. *Nat Neurosci* 2: 302-309.
25. Mariani J, Coppola G, Zhang P2, Abyzov A3, Provini L1, et al. (2015) FOXG1-Dependent Dysregulation of GABA/Glutamate Neuron Differentiation in Autism Spectrum Disorders. *Cell* 162: 375-390.
26. Gneccchi M, Zhang Z, Ni A, Dzau VJ (2008) Paracrine mechanisms in adult stem cell signaling and therapy. *Circ Res* 103: 1204-1219.
27. Khalili MA, Anvari M, Hekmati Moghadam SH, Sadeghian Nodoushan F, Fesahat F, et al. (2012) Therapeutic benefit of intravenous transplantation of mesenchymal stem cells after experimental subarachnoid hemorrhage in rats. *J Stroke Cerebrovasc Dis.* 21: 445-451
28. Chen A, Siow B, Blamire AM, Lako M, Clowry GJ (2010) Transplantation of magnetically labeled mesenchymal stem cells in a model of perinatal brain injury. *Stem Cell Res* 5: 255-266.